



CLASS I AND CLASS II AMALGAM RESTORATIONS

DR. SAGAR KHANNA

PROFESSOR

DEPARTMENT OF CONSERVATIVE DENTISTRY & ENDODONTICS

CONTENTS

- ▶ Introduction
- ▶ Indications
- ▶ Contraindications
- ▶ Advantages
- ▶ Disadvantages
- ▶ Clinical technique for class I amalgam restoration
- ▶ Clinical technique for class II amalgam restoration
- ▶ Conclusion
- ▶ Reference

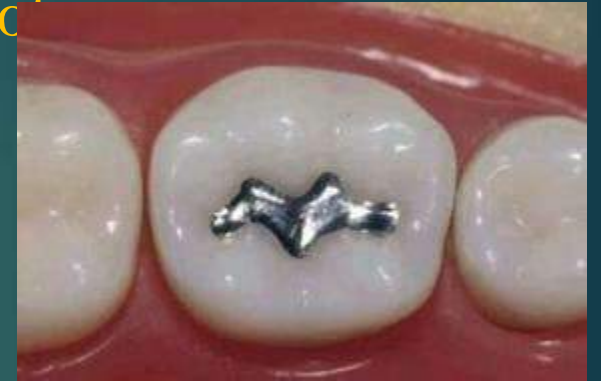INTRODUCTION

Amalgam is used for the restoration of many carious or fractured posterior teeth and in the replacement of failed restorations.

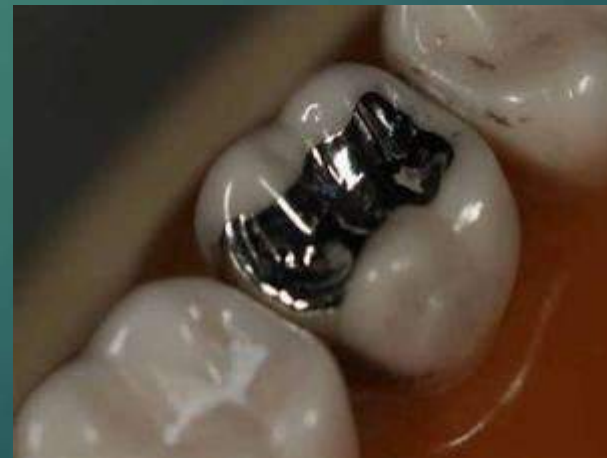Understanding the physical properties of amalgam and the principles of tooth preparation is necessary to produce amalgam restorations that provide optimal service. Careful evaluation of existing amalgams is important because they have the potential to provide long-term clinical service and should not be replaced unless an accurate diagnosis is made.

Here we would be looking for class I and class II amalgam restorations where :

1] Class I restorations restore defects on the occlusal surface of posterior teeth, the occlusal two-thirds of the facial and lingual surface of molars, and the lingual surfaces of maxillary incisors.



2] Class II restorations restore defects that affect one or both of the proximal surfaces of posterior teeth.



INDICATIONS

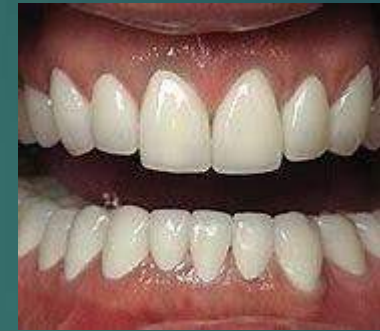Amalgam is indicated for the restoration of a Class I, II, and VI defect when the defect

- (1) Is not in an area of the mouth where esthetics is highly important,
- (2) Is moderate to large,
- (3) Is in an area that will have heavy occlusal contacts,
- (4) Cannot be well isolated,
- (5) Will become a foundation for a full coverage restoration, and
- (6) Is in a tooth that serves as an abutment for a removable partial denture.

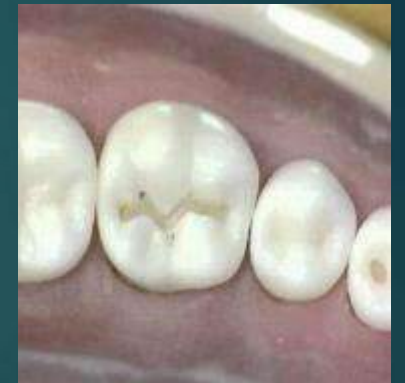CONTRAINDICATIONS

Although amalgam has no specific contraindications for use in Class I, II, and VI restorations, relative contraindications for use include

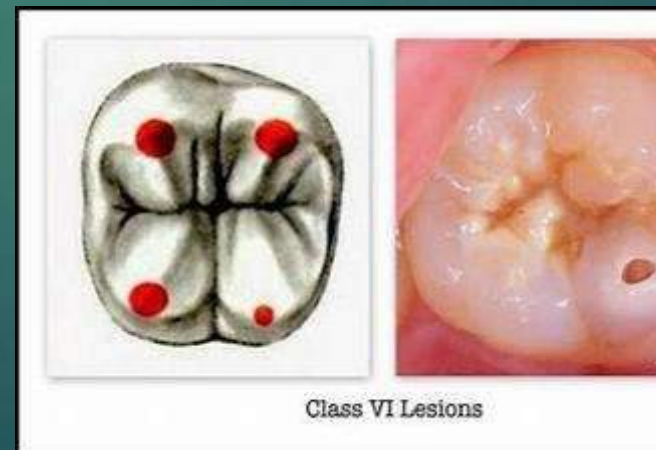
(1) Esthetically prominent areas of posterior teeth,



(2) Small to moderate Class I and II defects that can be well isolated and,



(3) Small class VI defects



ADVANTAGES

Primary advantages are the ease of use and the simplicity of the procedure. As noted in the following sections, the placing and contouring of amalgam restorations are generally easier than those for composite restorations.

DISADVANTAGES

The primary disadvantages of using amalgam for

Class I, II, and VI defects are

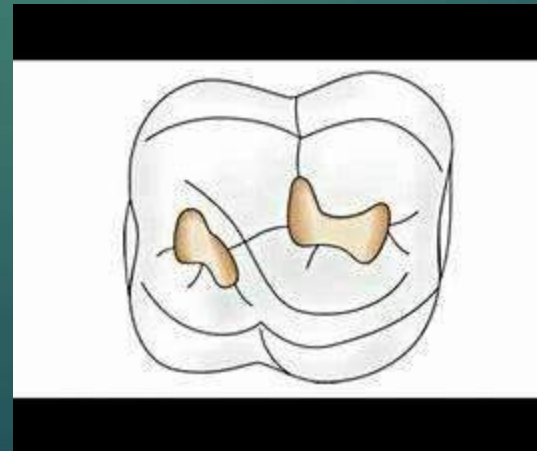
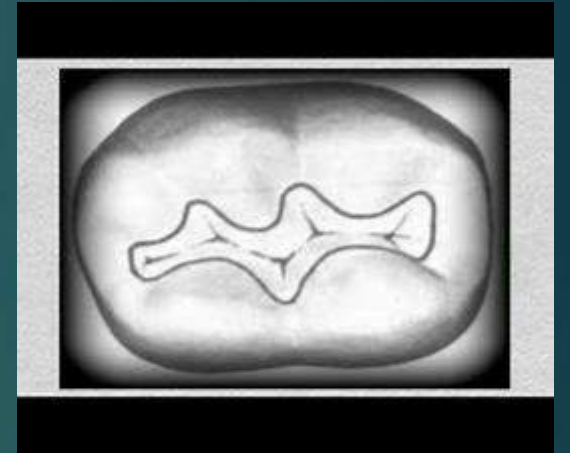
(1) Amalgam use requires more complex and larger tooth preparations than composite resin, and

(2) Amalgams may be considered to have a non-esthetic appearance by some patients.

CLINICAL TECHNIQUE FOR CLASS I AMALGAM RESTORATIONS

CONSERVATIVE CLASS I AMALGAM RESTORATIONS

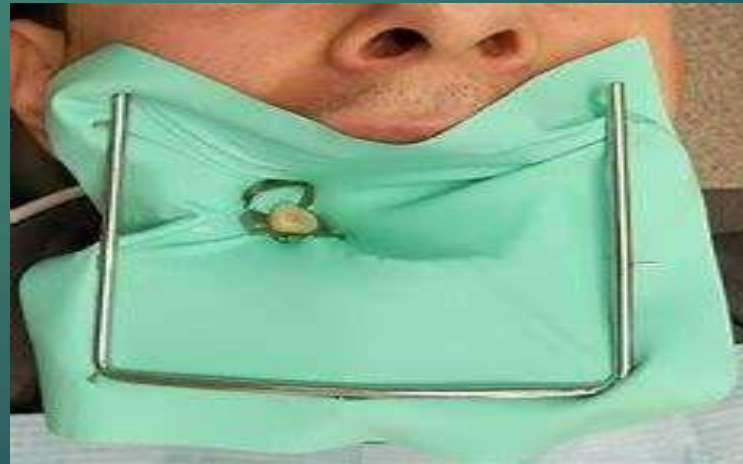Conservative tooth preparation is recommended to protect the pulp, preserve the strength of the tooth. Conservative preparation also enhances marginal integrity and restoration longevity, and reduce deterioration of the amalgam restoration.



INITIAL CLINICAL PROCEDURES

After the onset of profound anesthesia, isolation with the rubber dam is recommended to gain control over the operating field and for mercury hygiene.

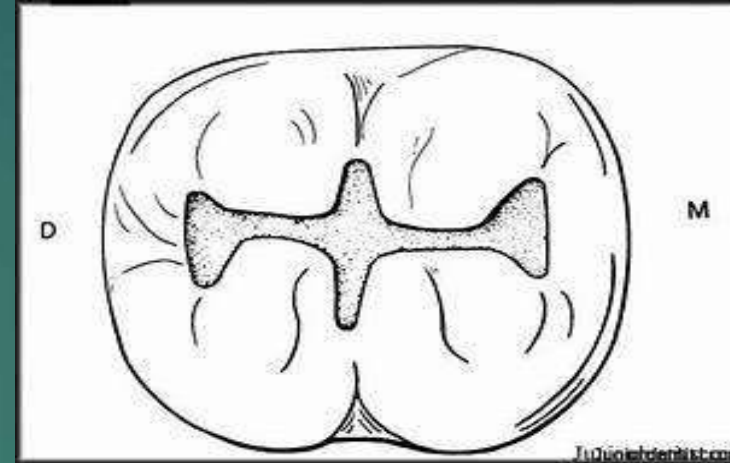
A pre-operative assessment of the occlusal relationship of the involved and adjacent teeth also is necessary.



TOOTH PREPARATION

1] INITIAL TOOTH PREPARATION

a] OUTLINE FORM



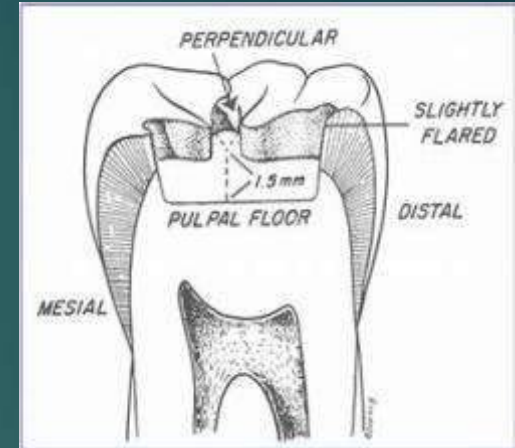
Initial tooth preparation is defined as establishing the outline form by extension of the external walls to sound tooth structure while maintaining a specified, limited depth and providing resistance and retention forms. The outline form for the Class I occlusal amalgam tooth preparation should include only the defective occlusal pits and fissures.

b] PRIMARY RESISTANCE FORM

Resistance form preparation features help the tooth, and the restoration to resist fractures caused by occlusal forces.

c] PRIMARY RETENTION FORM

Retention form preparation features help the restoration to prevent from displacement by tipping or lifting forces.



d] CONVENIENCE FORM

Convenience form includes features that allow adequate access and visibility of the operating site to facilitate tooth preparation and restoration.

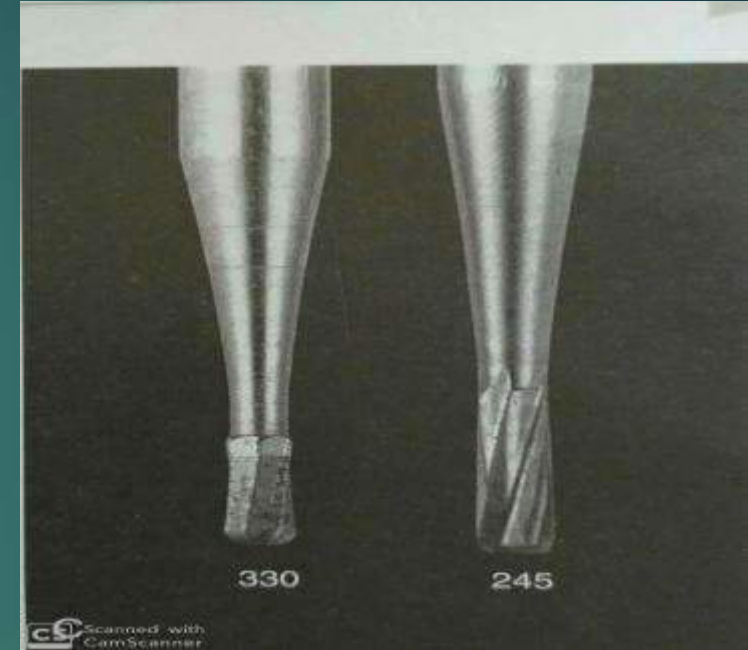
CLINICAL TECHNIQUE

ARMAMENTARIUM

No. 245 and No. 330 burs

Has bur length of 3mm and tip diameter of 0.8mm.

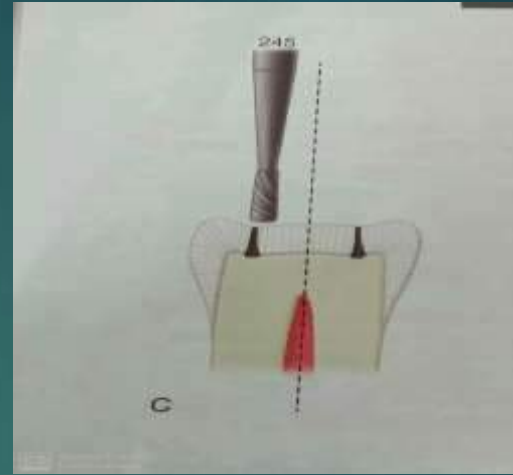
The no. 330 is smaller than no. 245 according to which we prepare conservative and conventional preparation respectively.



PROCEDURE

STEP 1

Enter the deepest or most carious pit with a **punch cut** using a no. 245 bur.

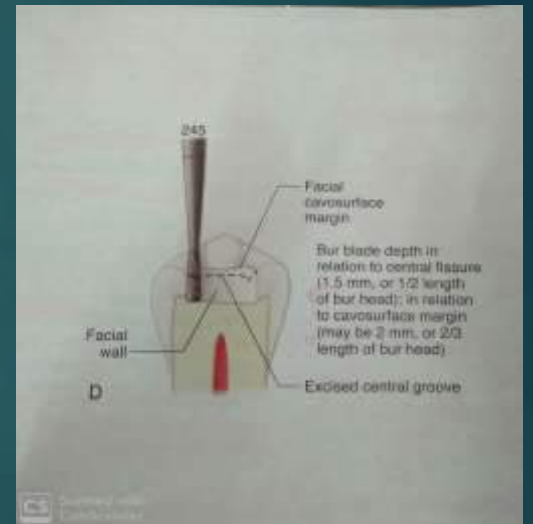
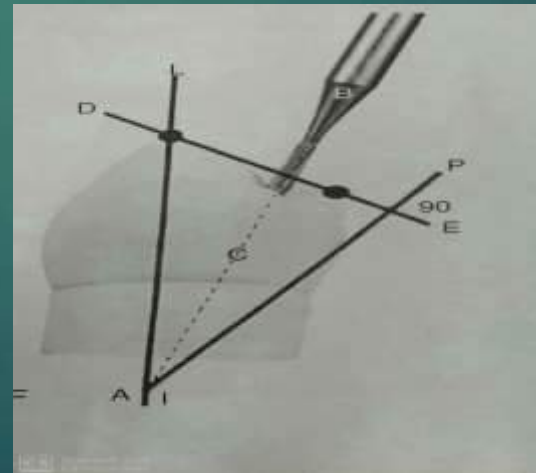


STEP 2

As the bur enters the pit, a proper depth of 1.5mm should be established.

STEP 3

It is taken into consideration that we enter the pit along the long axis of the tooth.



STEP 4

When the pits are equally defective, the distal pit should be entered

STEP 5

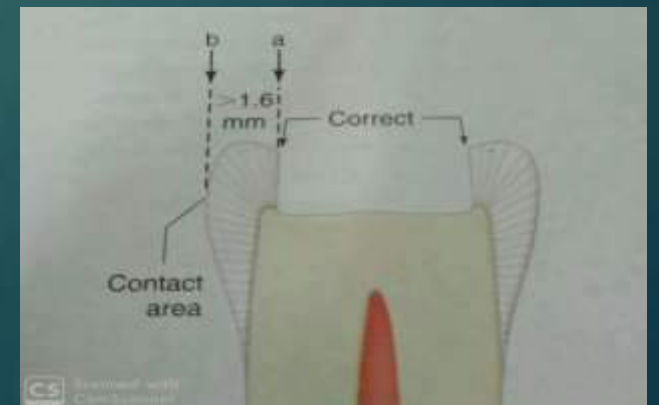
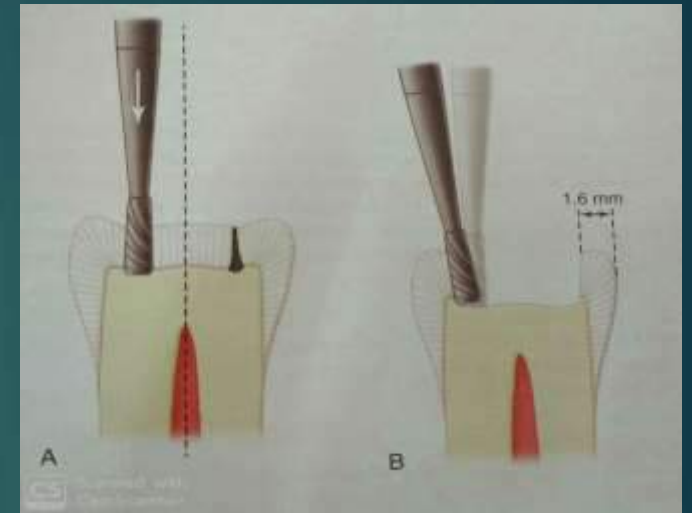
The bur should be positioned such that its distal aspect is directly over the distal pit, minimizing extension into the marginal ridge.

STEP 6

Distal extension into the distal marginal ridge to include a fissure or caries occasionally requires a slight tilting of the bur distally (≤ 10 degrees).

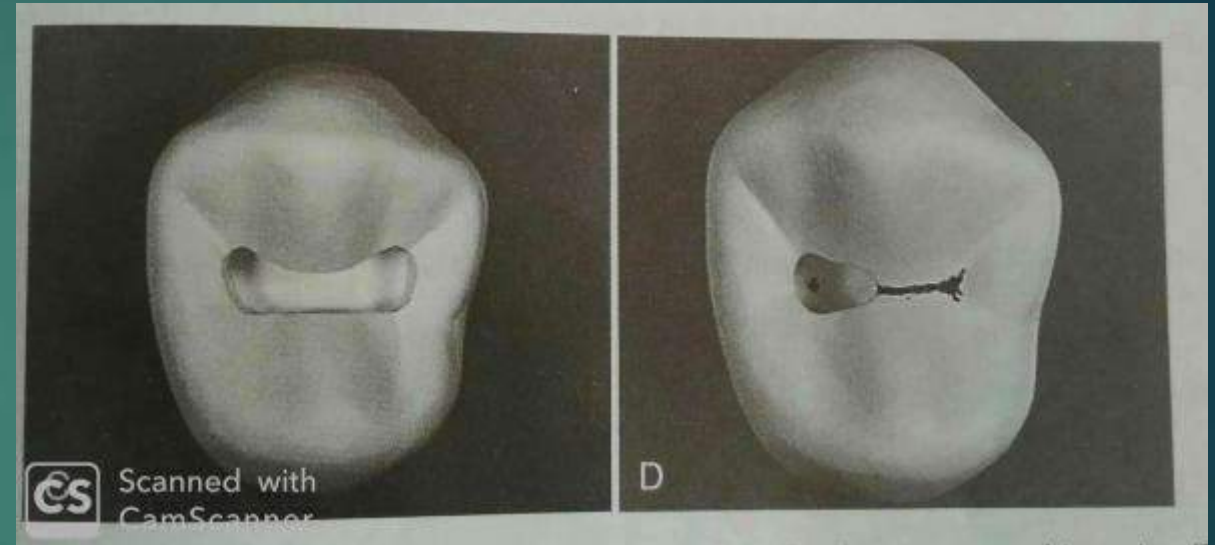
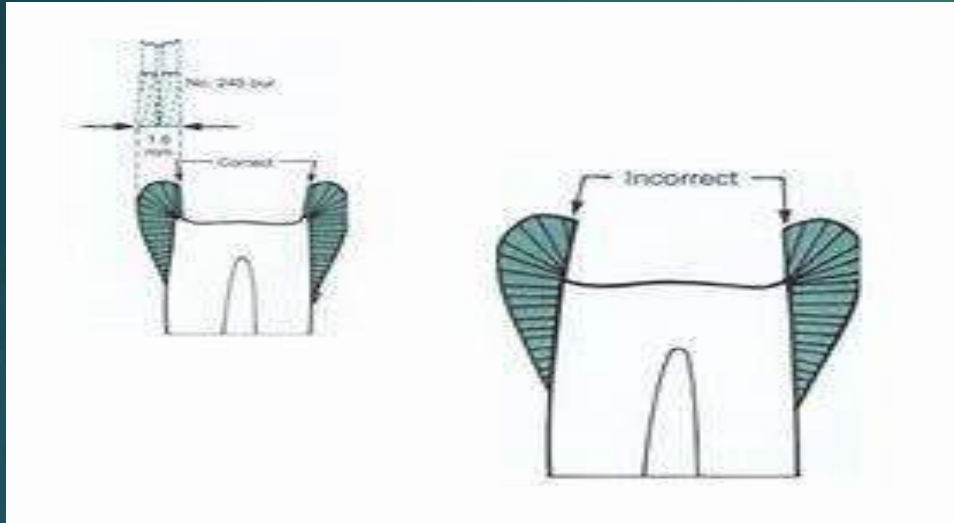
STEP 7

Proper marginal ridge width should be attained, i.e. 1.6mm in case of premolars and 2mm in case of molars



STEP 8

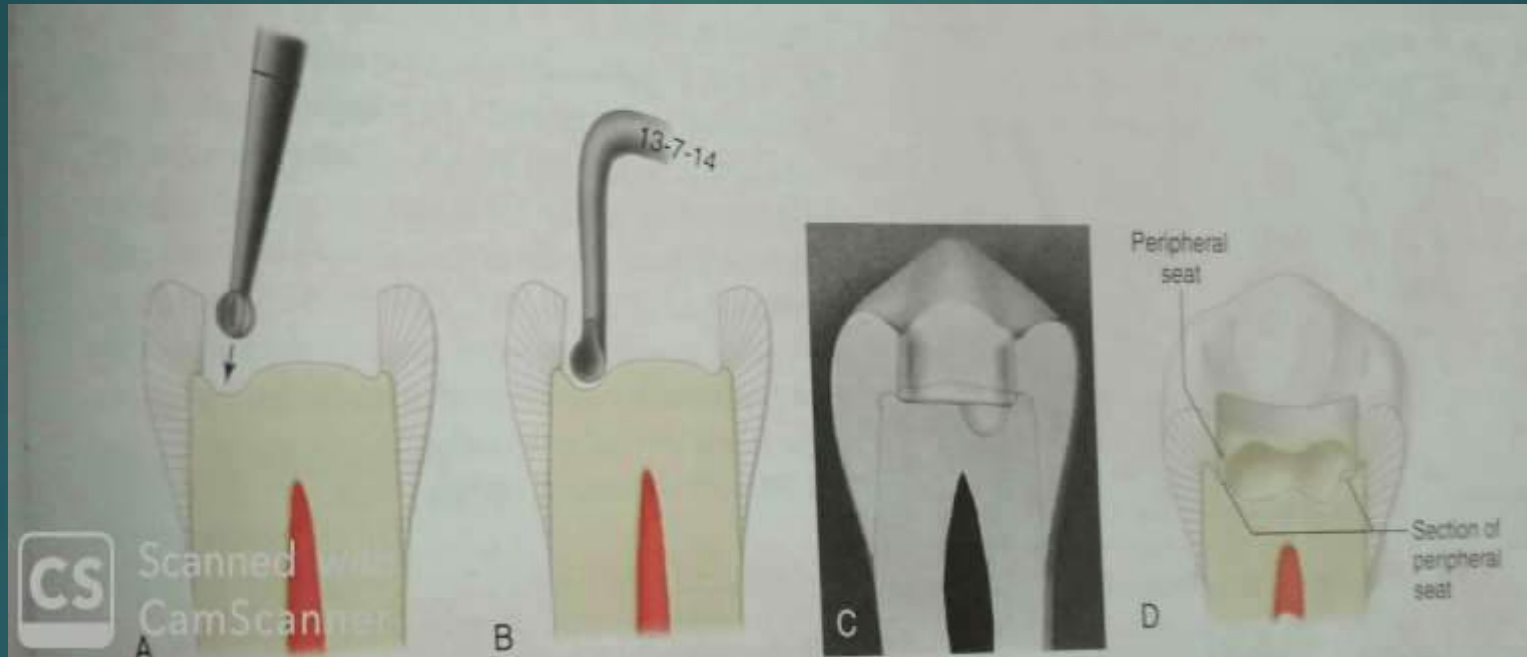
While maintaining the bur's orientation and depth, the preparation is extended distofacially or distolingually to include any fissures that radiate from the pit.



This completes the initial tooth preparation procedure for a class I amalgam restoration. The initial preparation should ensure that all the caries lesion is removed from the DEJ, resulting in a very narrow peripheral seat of healthy dentin on the pulpal wall surrounding any remaining caries located in the center of the pulpal wall.

2] FINAL TOOTH PREPARATION

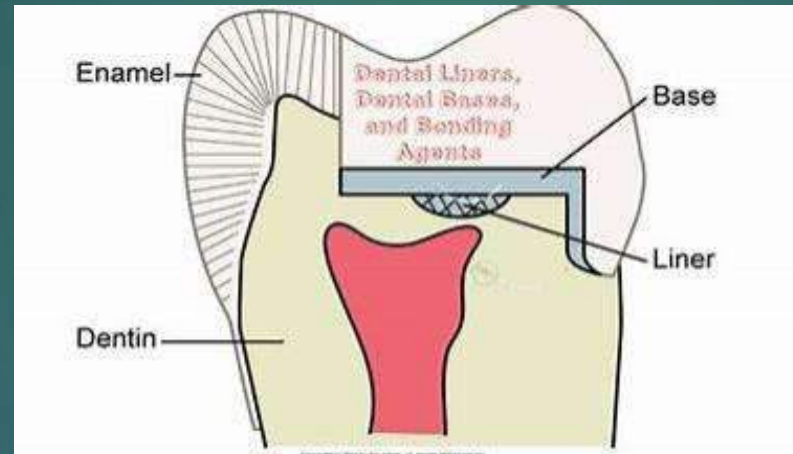
a] Removal of remaining defective enamel and infected dentin along with old restorative material



Removal of the remaining lesion is best accomplished using a discoid-type spoon excavator or a slowly revolving round carbide bur of appropriate size.

b) Pulp protection (where indicated)

The reason for using liners or bases is to protect the pulp or to aid pulpal recovery or both. It is desirable to have approximately a 2 mm dimensions of bulk between the pulp and a metallic restorative material . This bulk may include remaining dentin, liner, or base.

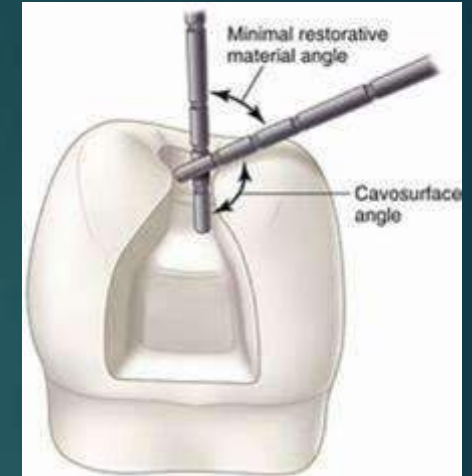


c) Secondary resistance and retention form

It is achieved by mechanical features such as retention grooves, pins and slots etc.

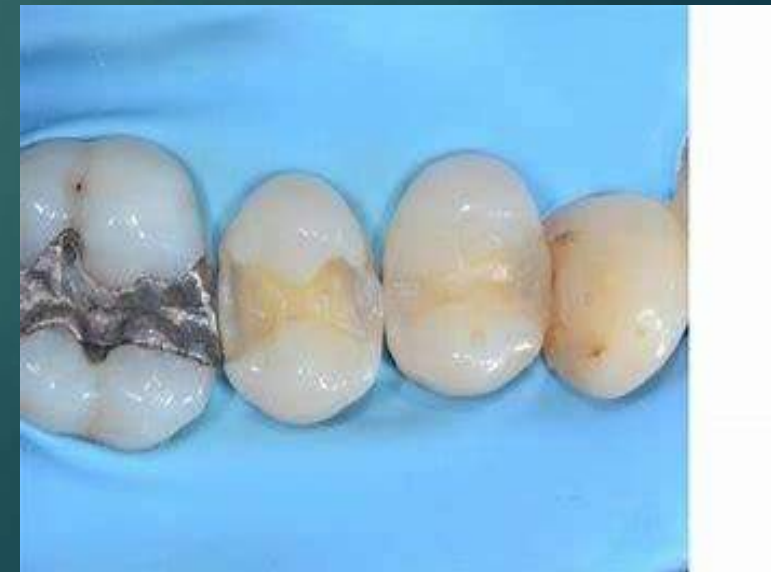d) Procedures for finishing the external walls of the preparation

External walls may already have been finished during initial preparation steps; however, operator assessment of the external walls of the preparation is accomplished at this point. It is important to provide an approximate 90- to 100-degree cavosurface angle, which should result in 80- to 90-degree amalgam at the margins. Provides strength to both.



e) Final Procedures – Cleaning, inspecting and desensitizing

The completed tooth preparation should be inspected and cleaned before restoration. The tooth preparation should be free of debris after the tooth has been rinsed with the air-water syringe.



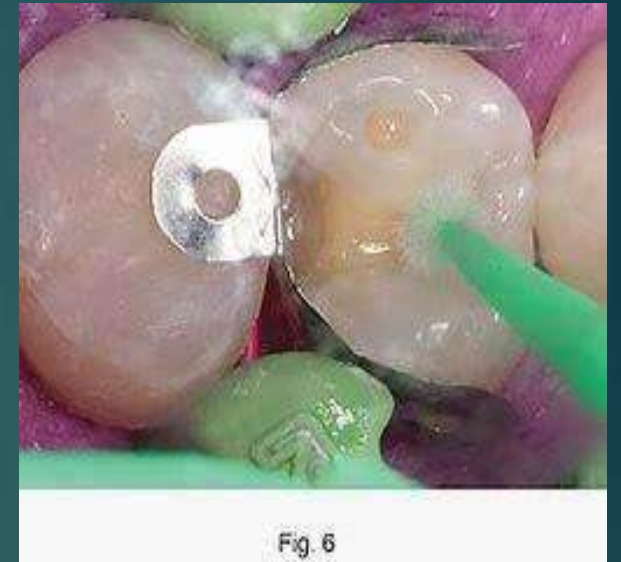
RESTORATIVE TECHNIQUE FOR CLASS I AMALGAM RESTORATION

a) Desensitizer Placement

A dentin desensitizer is placed in the preparation before amalgam condensation.

The dentin desensitizer is applied onto the prepared tooth surface according to manufacturer's recommendations; excess moisture is removed without desiccating the dentin; and then the amalgam is condensed into place.

Commonly used desensitizers are **5% glutaraldehyde** and **35% 2- hydroxyethyl methacrylate (HEMA)**.



b) INSERTION AND CARVING OF AMALGAM

➤ CLINICAL CONSIDERATIONS

- ❑ High copper amalgam is usually recommended.
- ❑ Amalgam should be triturated according to manufacturer's recommendation.
- ❑ The mixed amalgam should not be crumbly and dry, should have sufficient '**wetness**' to aid in achieving a well adapted restoration.

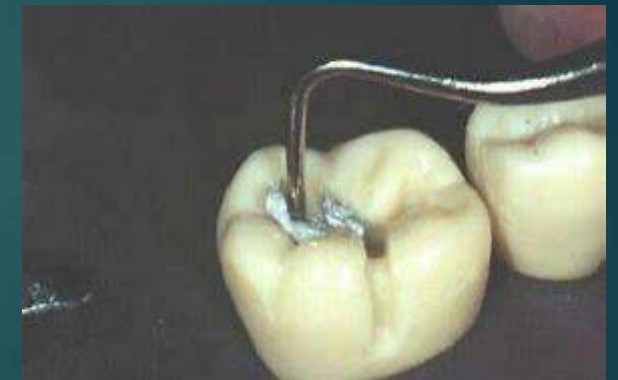
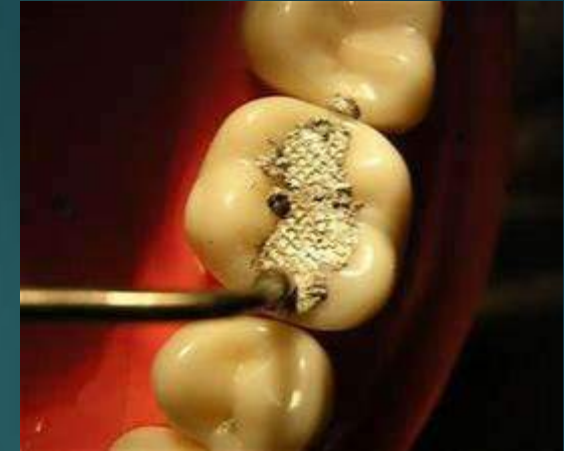
➤ AMALGAM CONDENSATION

The objective is to adapt it to the preparation walls and produce a restoration free of voids thereby reducing marginal leakage, along with necessary minimization of mercury content to decrease corrosion and to enhance strength and marginal integrity.

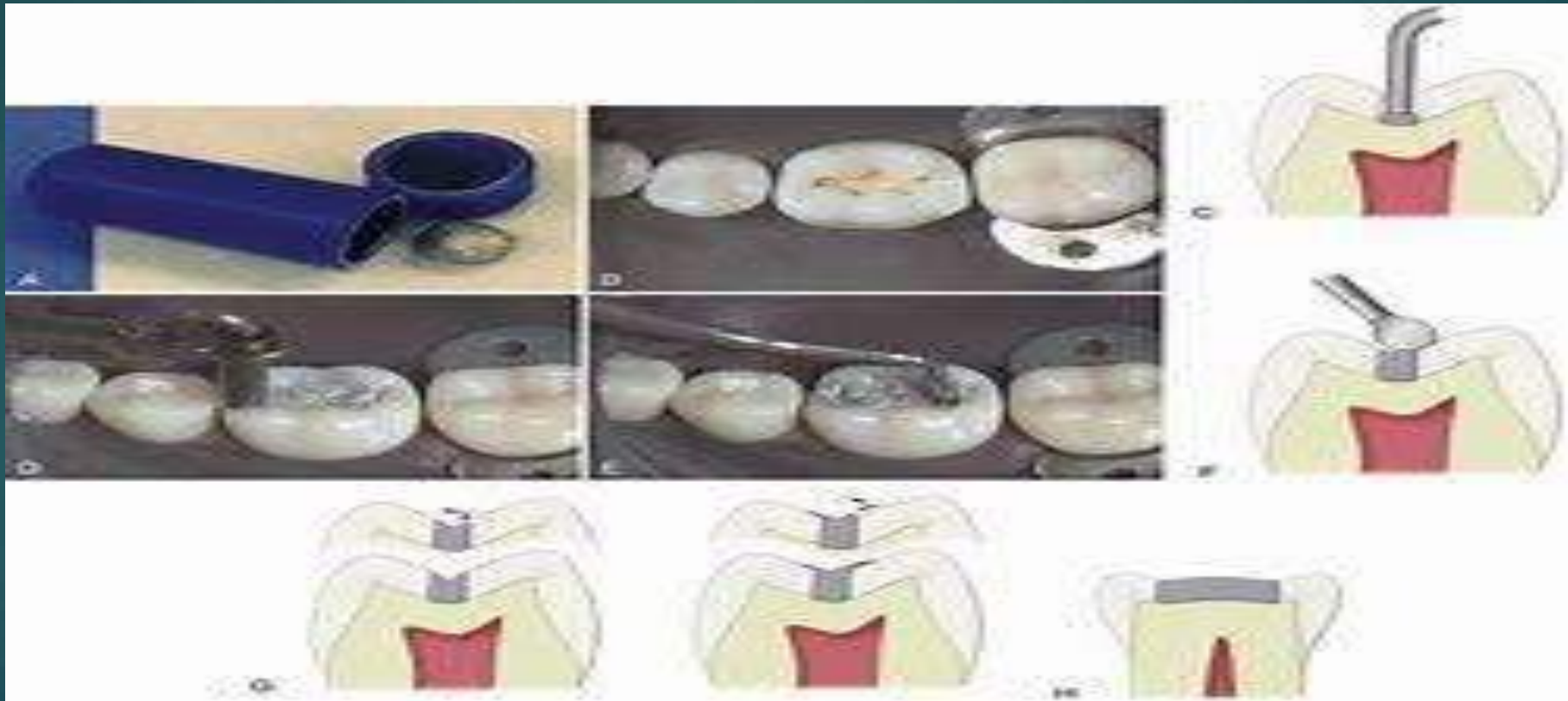➤ INSERTION AND CARVING OF AMALGAM

- ❑ An **amalgam carrier** should be used to transfer amalgam in the preparation.
- ❑ A **flat-faced, circular or elliptic condenser** should be used to condense amalgam over the pulpal floor. It should be properly condensed into pulpal line angles.
- ❑ **Smaller condensers** are indicated for initial increments.
- ❑ **Larger condensers** are used while overpacking.
- ❑ Each condensed increment should fill only **one-third to one-half** of the preparation depth.
- ❑ Each preparation should be **overpacked by 1mm** to ensure that cavosurface margins are completely packed.



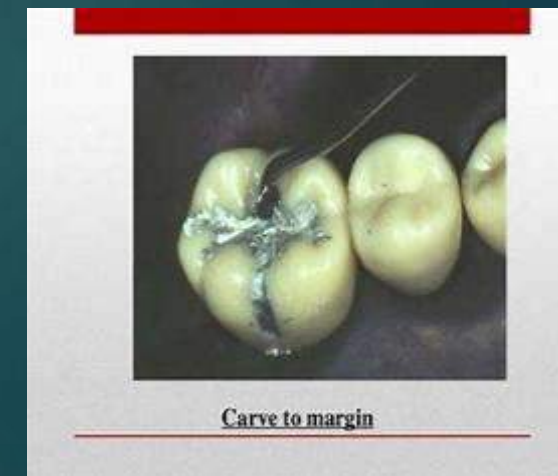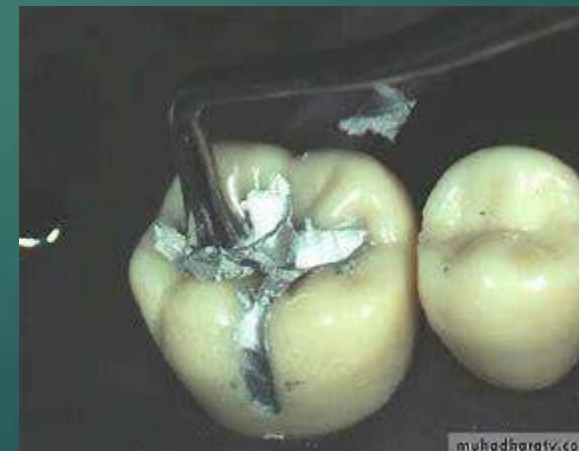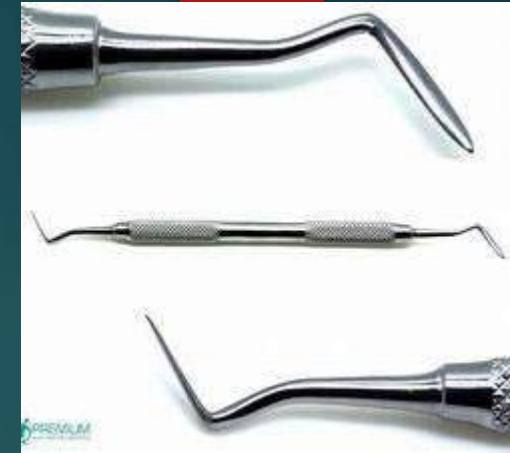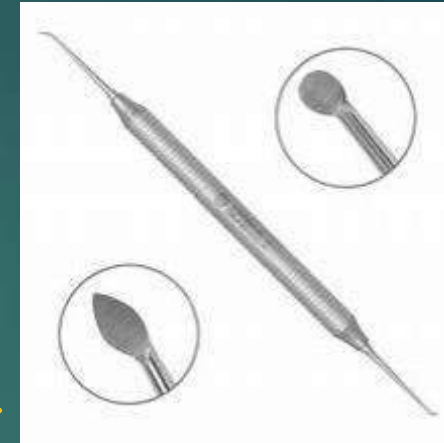
➤ PRECARVE BURNISHING

To ensure that the marginal amalgam is well condensed before carving, the overpacked amalgam should be burnished immediately with a large burnisher, using strokes mesiodistally and faciolingually, which is referred to as precarve burnishing.



➤ CONTOURING AND FINISHING OF AMALGAM

- ❑ Sharp discoid-cleoid carvers of suitable sizes are useful for this. The larger end of the discoid-cleoid instrument (No. 3/6) is used first, followed by the smaller instrument (No. 4/5) in regions not accessible to the larger instrument.
- ❑ Deep occlusal grooves should not be carved ,because it may cause chipping at the margins, causing weakening of the restoration.
- ❑ Undercarving leaves thin portions of amalgam on the unprepared tooth surface. This thin portion of amalgam is called **flash**.

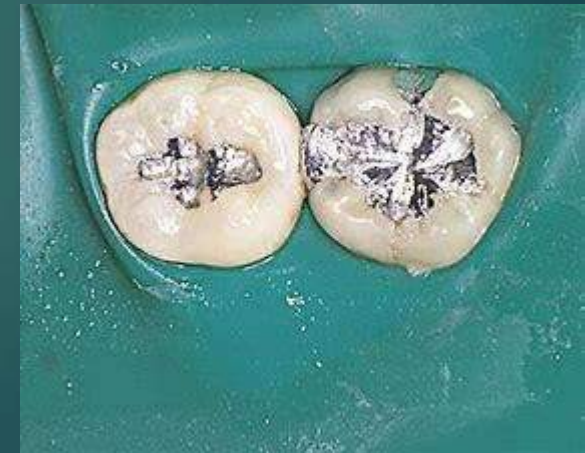
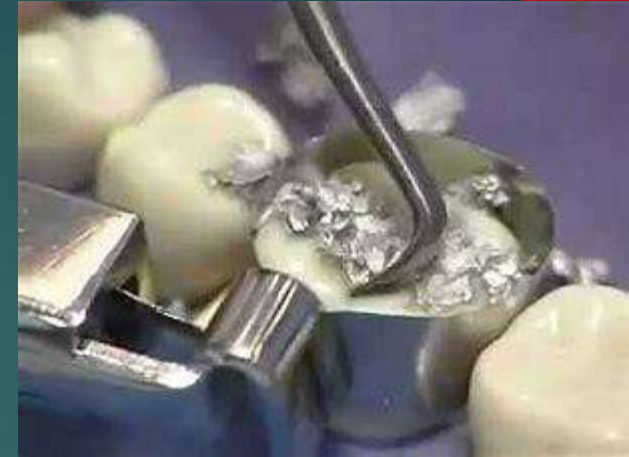
- ❑ All carving should be done with the edge of the blade perpendicular to the margins and instrument moved parallel to the margins.

- ❑ Overcarving and undercarving should be prevented .

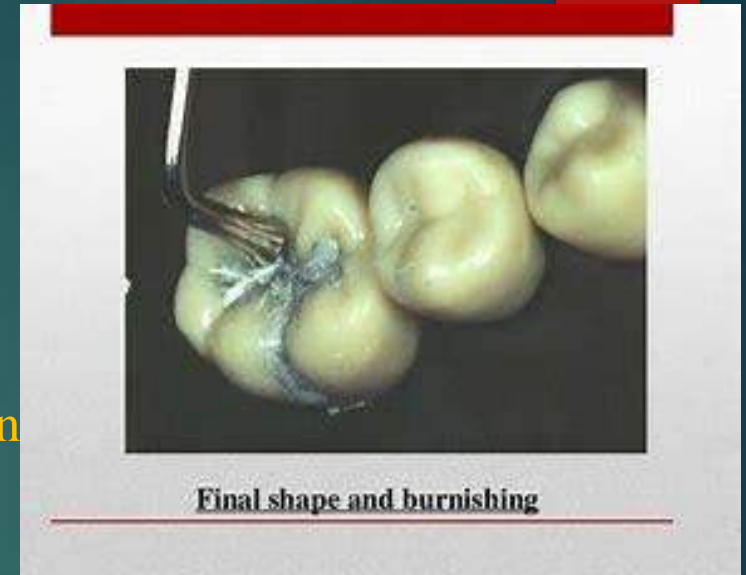
- ❑ An amalgam carving that is larger and or irregular is **undercarved** and requires further carving or finishing.

- ❑ An amalgam restoration that is **overcarved** should be replaced.



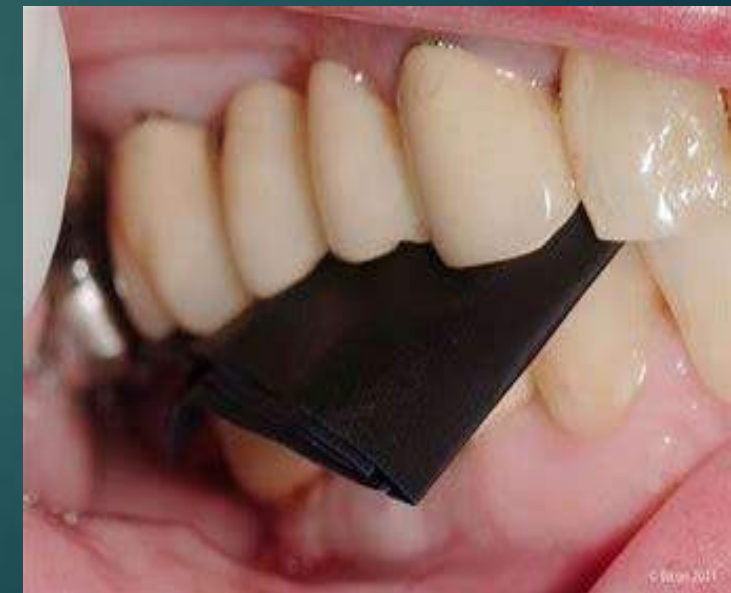➤ POST CARVE BURNISHING

- ❑ Post carve burnishing improves the marginal integrity of amalgam and may improve the smoothness of amalgam.
- ❑ The surface should not be rubbed hard enough to produce grooves in the amalgam.



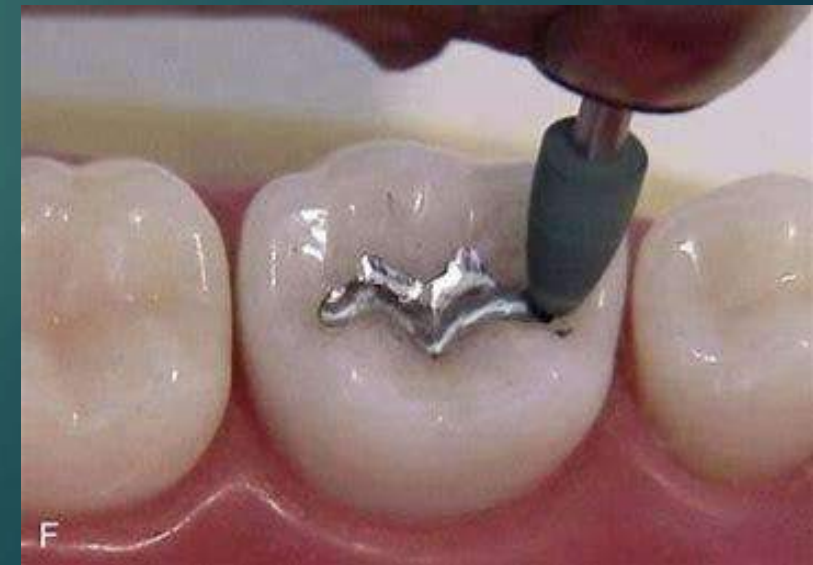➤ OCCLUSAL ADJUSTMENT

A piece of articulating paper is placed over the restoration, and the patient is instructed to close gently into occlusion.



▶ FINISHING AND POLISHING

- ❑ Additional finishing and polishing of amalgam are **not attempted within 24 hours** of insertion.
- ❑ It should be kept in mind that reduction of any occlusal contact should be avoided during polishing.
- ❑ **A, large round finishing bur** is generally used for finishing. The long axis of the bur should be at a 90 degree angle to the margin to allow unprepared tooth structure to guide and avoid unnecessary removal of amalgam.
- ❑ For polishing coarse, rubber abrasive point at **low speed** and air water spray to produce a smooth, satiny appearance is used. Speed should be low to avoid increase in temperature and damage to pulp.
- ❑ For high polish **medium grit or fine grit points** can also be used.



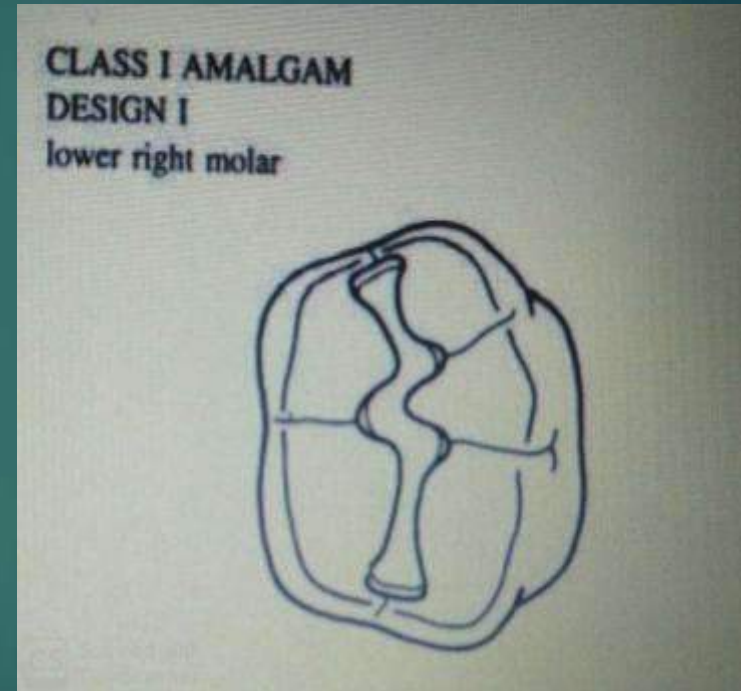
OTHER CLASS I AMALGAM RESTORATIONS

CLASS I DESIGN 1

Location: Occlusal surfaces of molars and premolars.

Indications:

- a. The caries cone penetration into dentin does not exceed 0.5 mm-1 mm.
- b. Due to caries the defect will not widen the preparation by more than one – fourth of the intercuspal width.



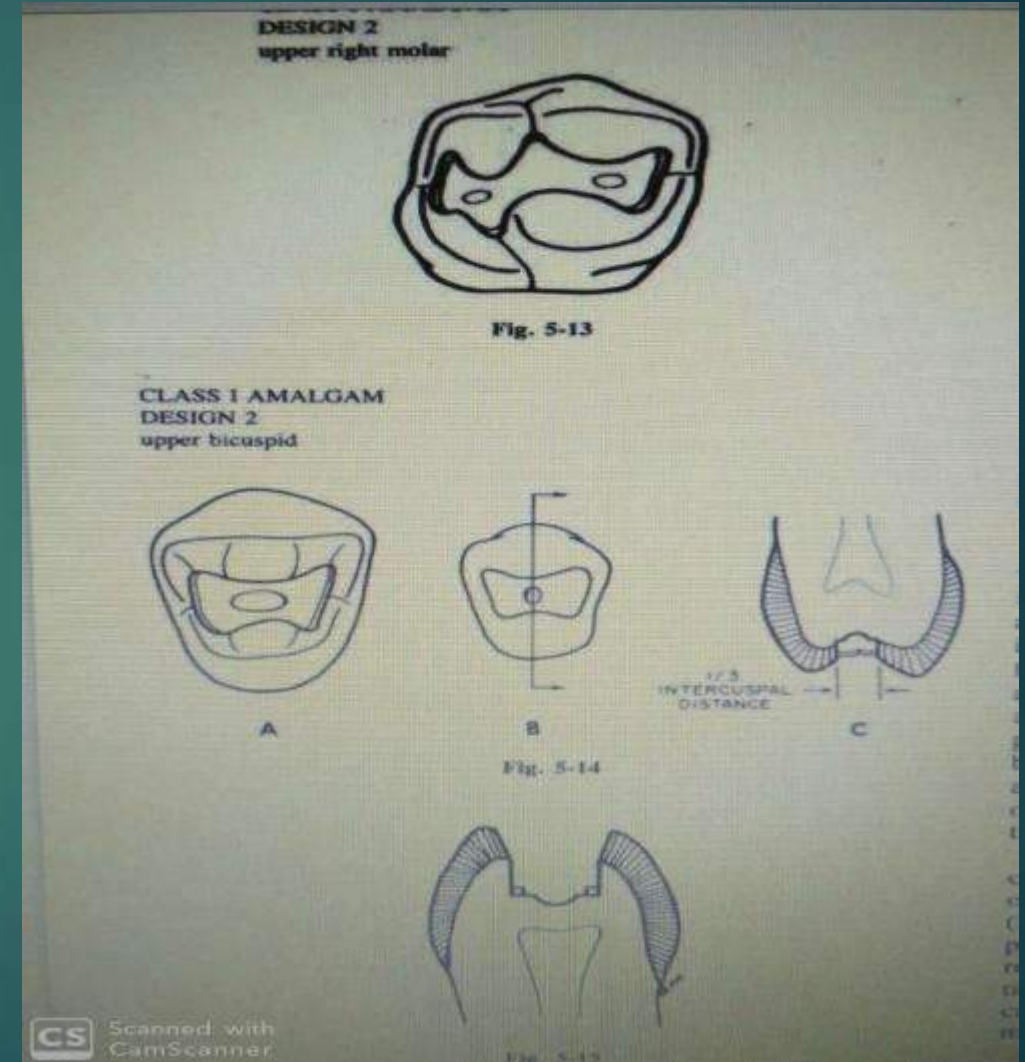
CLASS I DESIGN 2

Location

Occlusal surfaces of molars and premolars.

Indications:

- The caries cones in dentin extend 1 mm or more from the dentine-enamel junction at one or more points.
- The preparation involvement of the occlusal surface, due to cariogenic and anatomical considerations, and as a result of applying the **principles of extension for prevention**, is more than one-fourth of the intercuspal distance.



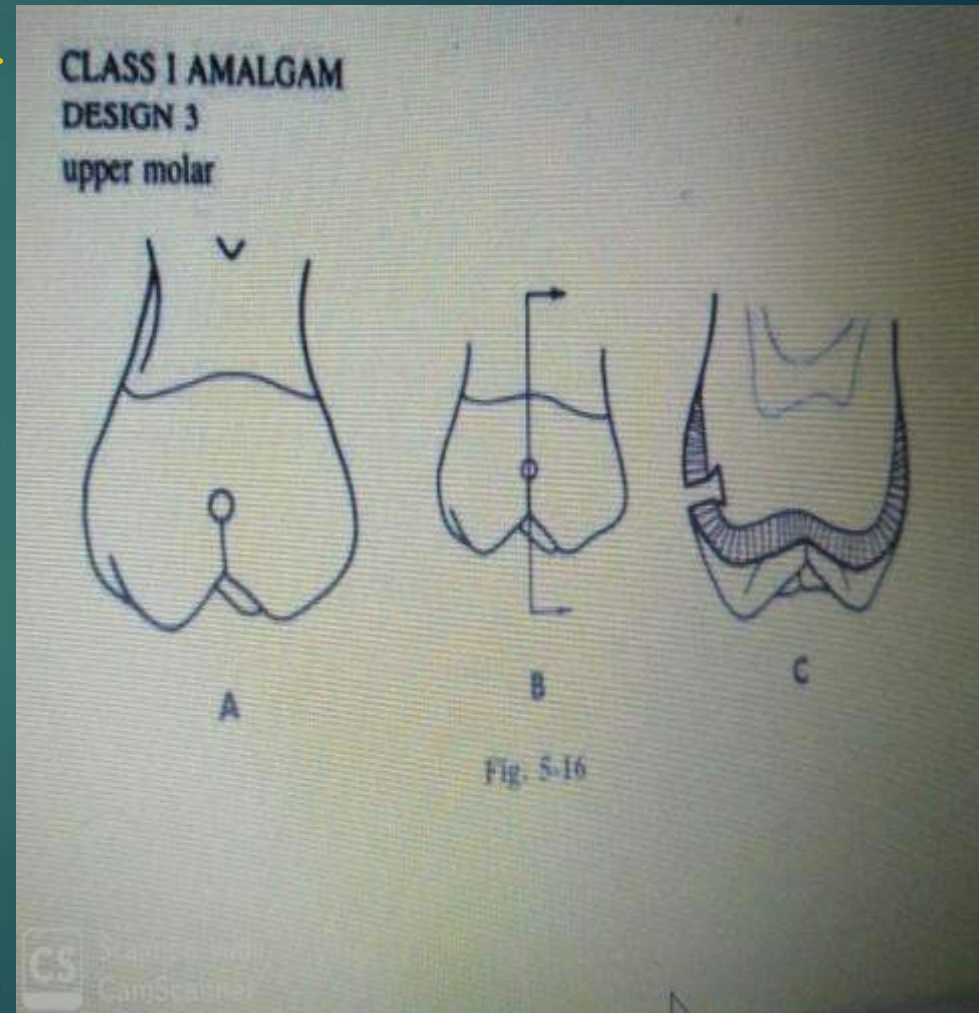
CLASS I DESIGN 3

Location:

In the occlusal one- to two-thirds of the facial and lingual surfaces of molars and on the lingual surfaces of upper anterior teeth, usually the lateral incisors.

Indications:

- pit or fissure in the aforementioned location is decayed.
- It is used to eradicate a pit or fissure in the aforementioned location as a **prophylactic measure** in decay-susceptible situations.
- The involved pit in this location is **not connected with other surface(s) or lesions in the tooth**, either externally-via a fissure or enamel lesion, or internally-by backward decay.



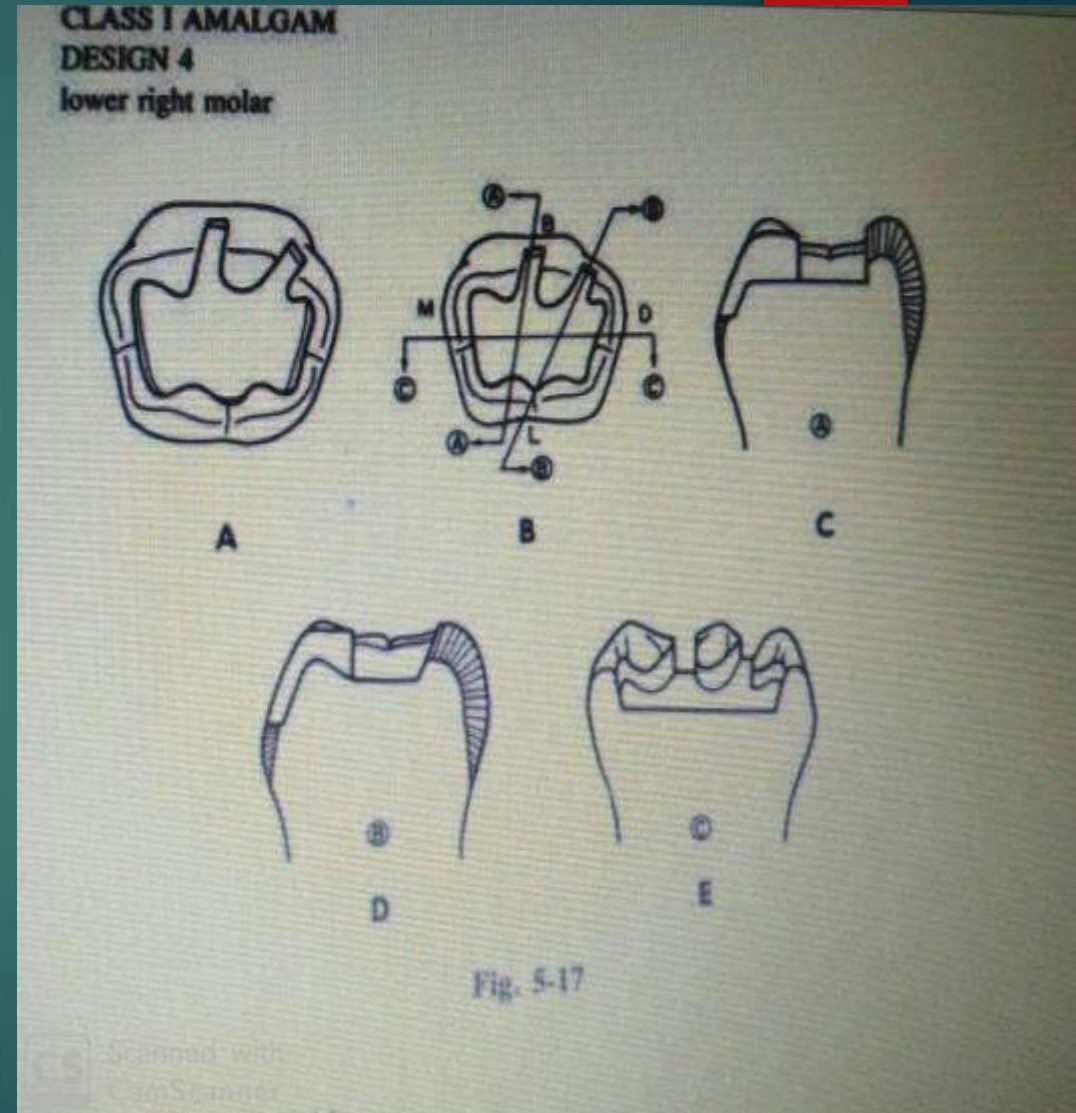
CLASS I DESIGN 4

Location:

This design is applied in molars where in addition to involving their occlusal surfaces, the **grooved part of the facial and/or lingual surfaces is also involved.**

Indications:

- Caries lesions at the facial or lingual pits are **connected to the occlusal surface or lesion through a fissure**, enamel decay, or backward decay.
- Decay undermines the facial or lingual marginal ridges, or thins them so they cannot be self-resistant.
- Caries cones, facially or lingually, are confined to the concavity of their corresponding grooves.



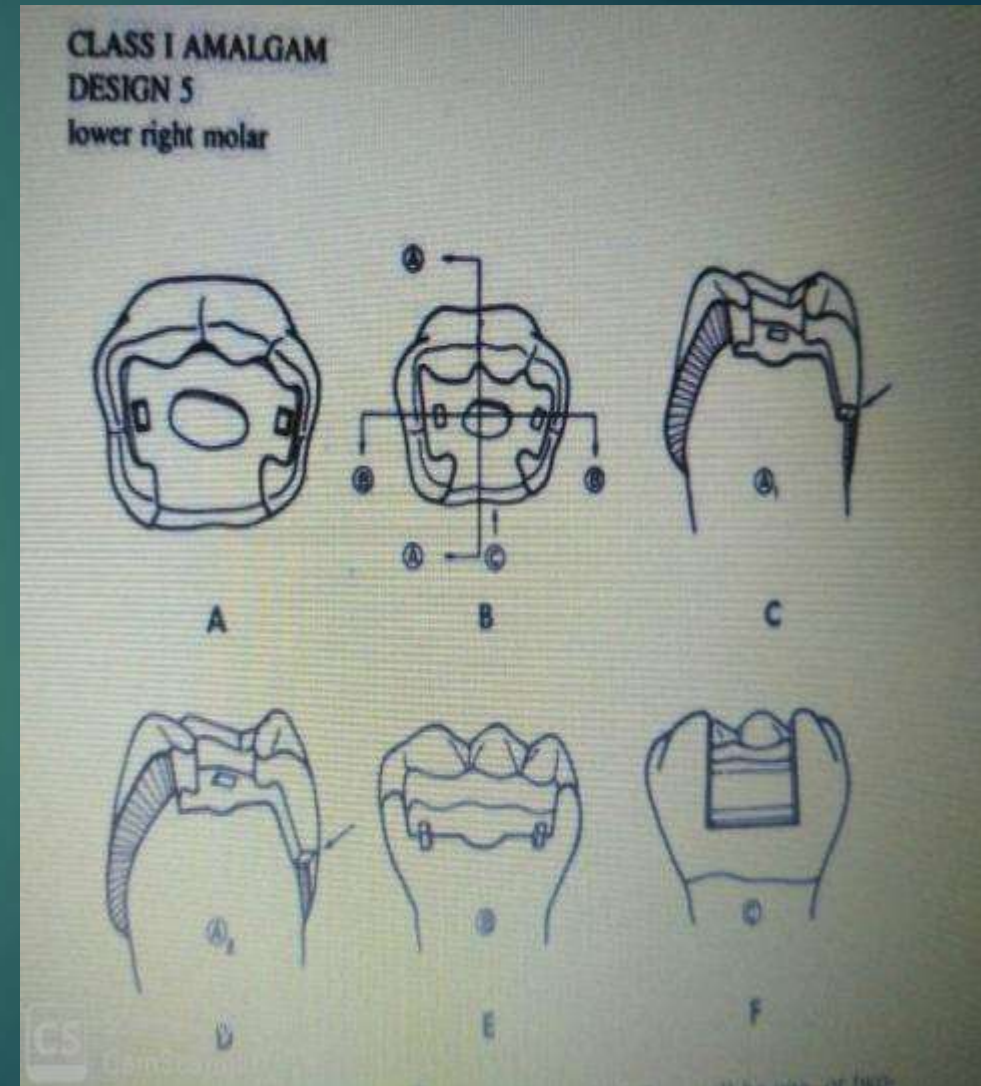
Class I, Design 5

Location:

This design is confined to molar teeth, where, in addition to involving part of the occlusal surface, **most or all of the facial and/or lingual surfaces are also included** in the cavity preparation.

Indications:

- Facial or lingual cusps are undermined by backward decay or directly attacked by forward decay, necessitating their total replacement by restorative materials.
- The outline of the occlusal surface is not conducive to retention of the restoration.
- The caries cones in dentin exceed 1 mm from the DEJ.



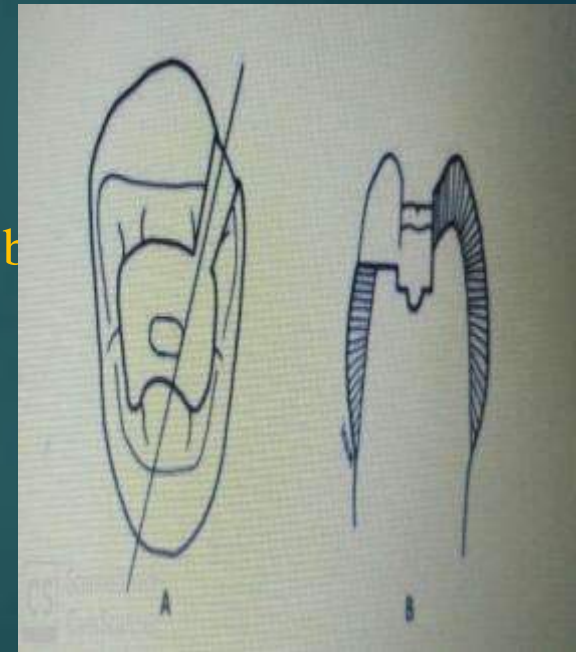
CLASS I DESIGN 6 (COMBINATION OF CLASS I AND CLASS VI)

Location:

This design of cavity preparation is used when it is necessary to include part of the **occlusal surfaces of molars or premolars as well as a portion of the facial, proximal or lingual surface** in the form of a "table" of an entire cusp (marginal ridge) or a section of a cusp (marginal ridge).

Indications :

- a. **Portions or an entire cusp are undermined** by backward decay, or badly thinned by direct decay, necessitating partial or total replacement of the cusp by a restorative material.
- b. The marginal ridge adjacent to an occlusal preparation is crossed by a fissure to the facial or lingual embrasures (mesial marginal ridges of upper, first premolar, distal marginal ridge or upper second molars).



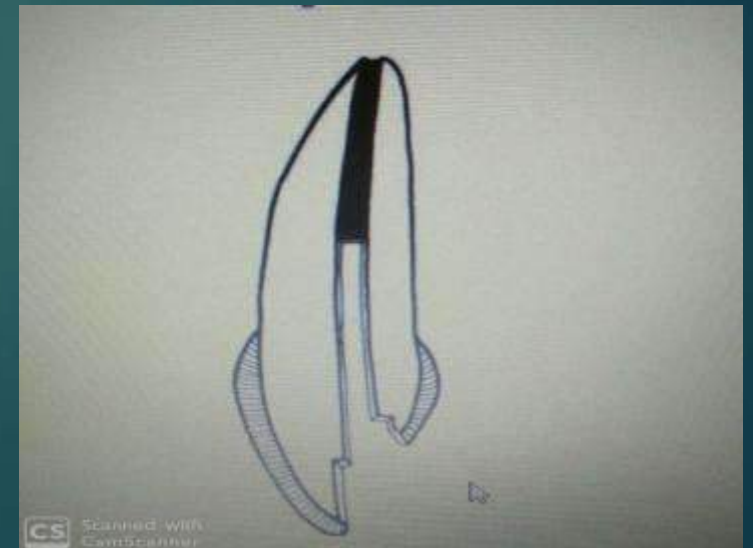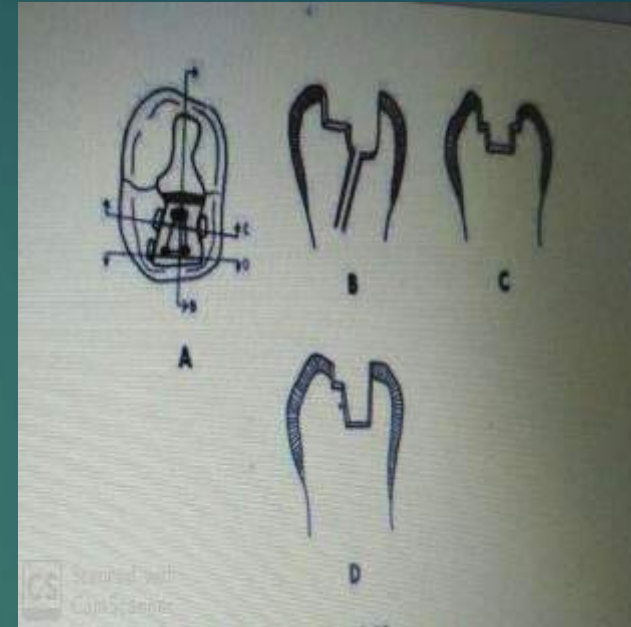
CLASS 1 DESIGN 8

Location:

In molars and premolars, this design is used on the occlusal and sometimes on the occlusal and/or facial-lingual surfaces . It also may be used on the lingual surfaces of anterior teeth.

Indications:

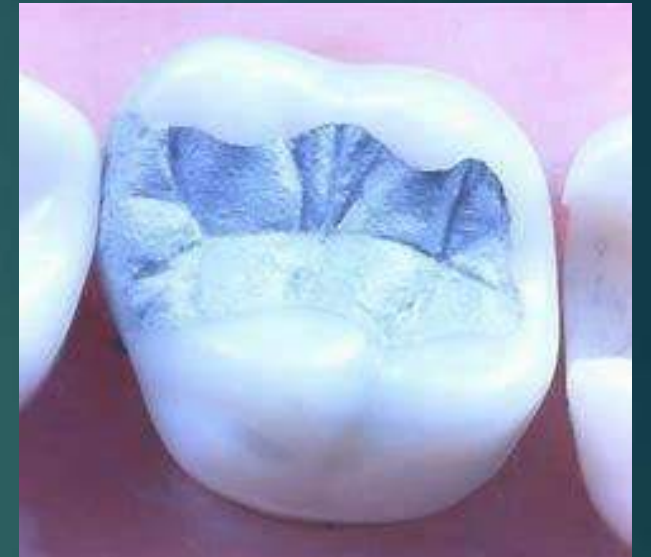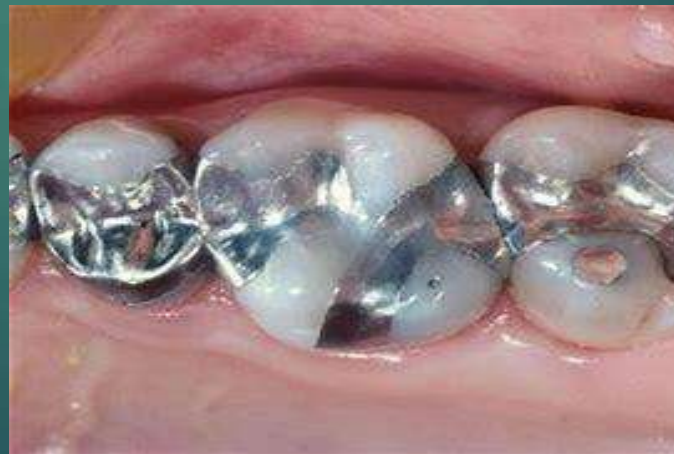These preparations are designed specifically for endodontically treated teeth and they are confined to the occlusal and lingual or buccal surfaces of these teeth.



CLINICAL TECHNIQUE FOR CLASS II AMALGAM RESTORATION

Amalgam restorations that restore one or both of the proximal surfaces of the tooth may provide years of service to the patient when

- (1) The tooth preparation is correct,
- (2) The matrix is suitable,
- (3) The operating field is isolated, and
- (4) The restorative material is manipulated properly



TOOTH PREPARATION

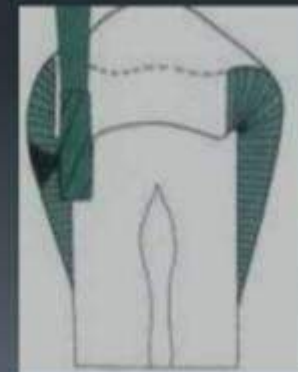
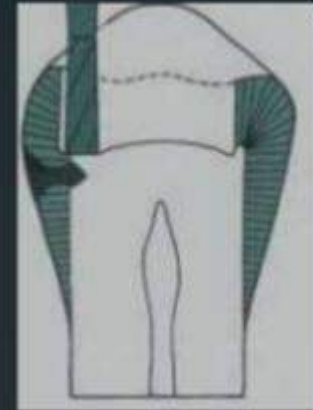
CLASS II AMALGAM RESTORATIONS INVOLVING ONLY ONE PROXIMAL SURFACE

➤ INITIAL TOOTH PREPARATION

I. OCCLUSAL OUTLINE FORM (OCCLUSAL STEP)

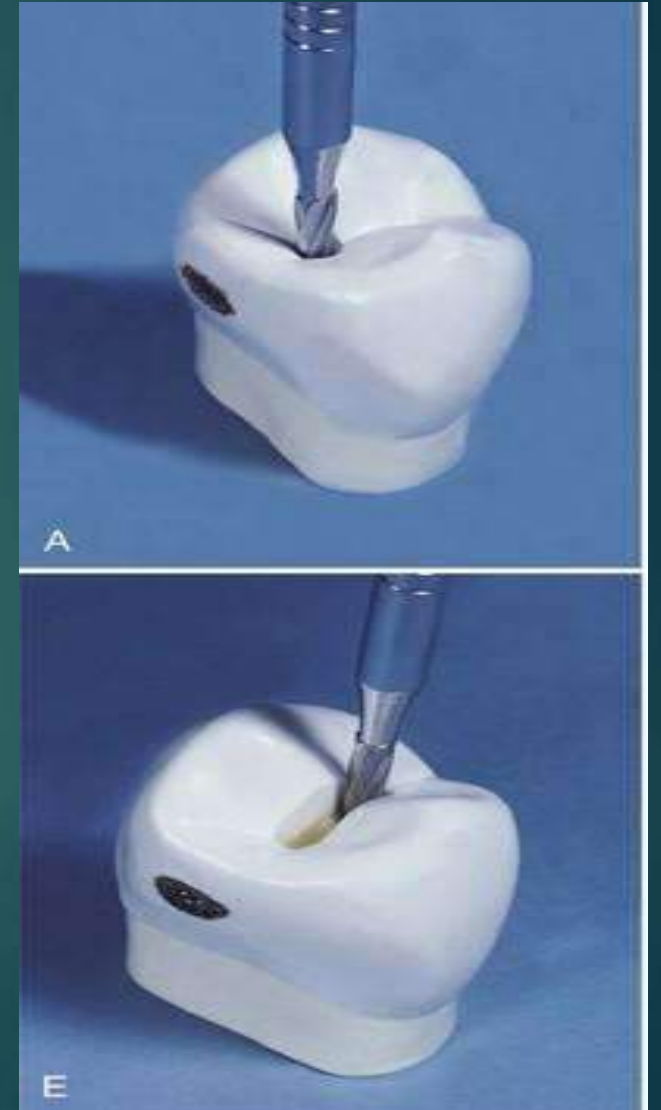
a) STEP 1 - Punch cut

- Using high speed with air-water spray, the operator enters the pit nearest the involved proximal surface with a punch cut using a No. 245 bur oriented along the long axis of the tooth.
- As the bur enters the pit, a target depth of 0.1–0.2 mm into dentin should be established, 1.5 mm as measured at the central fissure, and approximately 2 mm on the prepared external walls such that the DEJ is identified.



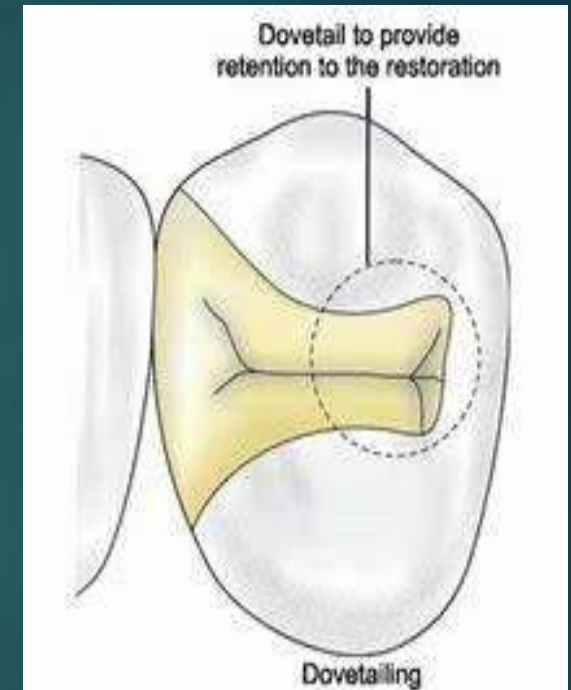
b) STEP 2- Occlusal extension

- While maintaining the same depth and bur orientation, the bur is moved to extend the outline to include the central fissure and the opposite pit.
- For the very conservative preparation, the isthmus width should be as narrow as possible, preferably no wider than one-quarter the intercuspal distance, ideally, it should be the width of the No. 245 bur.
- Maintaining the bur parallel to the long axis of the tooth crown creates facial, lingual with a slight occlusal convergence, which provides favorable amalgam angles at the margins.



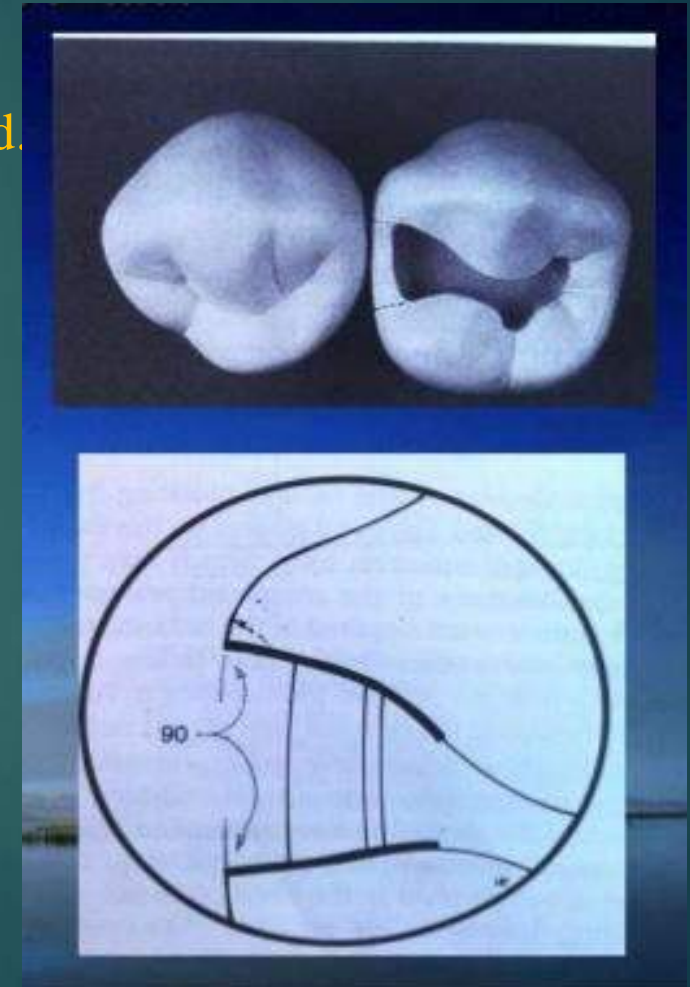
c) STEP 3 - Occlusal dovetail (if required)

- During development of the distal pit area of the preparation, extension to include any distofacial and distolingual developmental fissures radiating from the pit may be indicated.
- The distal pit area provides a dovetail retention form, which may prevent mesial displacement of the completed restoration.
- The dovetail feature is not required in the occlusal step of a single proximal surface preparation, unless a fissure emanating from an occlusal pit indicates it.



STEP 4 – Proximal extension

- The desired final location of the facial and lingual walls of the proximal box or the proximal outline form relative to the contact area is visualized.
- **Reverse curve** – The reverse curve is an S- shaped concave curve made by offsetting the outline form of the isthmus where it joins the outline form of the outline form of proximal box.
- While maintaining the established pulpal depth and with the bur parallel to the long axis of the tooth crown , the preparation is extended to the proximal side stopping approximately **0.8mm** short of cutting through the marginal ridge into the contact area.



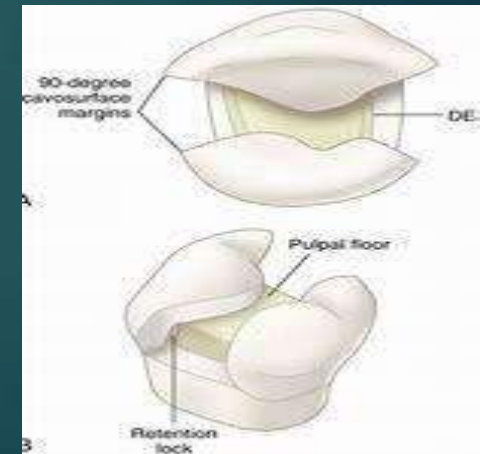
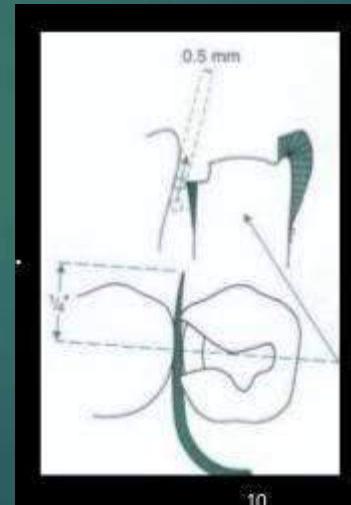
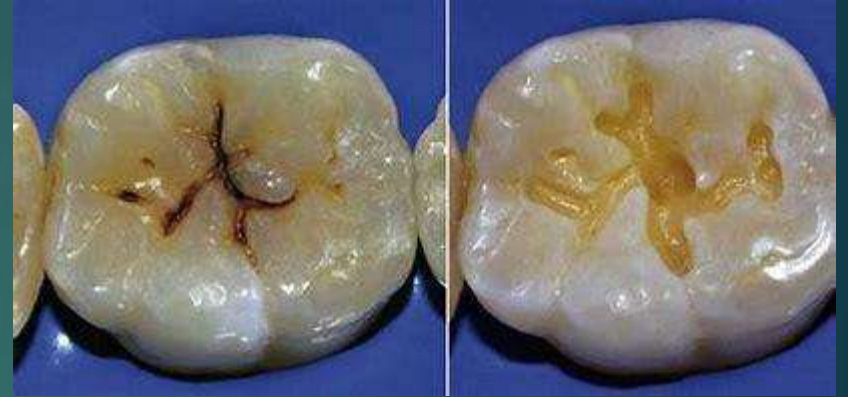
II. PROXIMAL OUTLINE FORM (PROXIMAL BOX)

The objectives of the extension of proximal margins are as follows:

(1) include all caries lesion, defects, or existing restorative material;

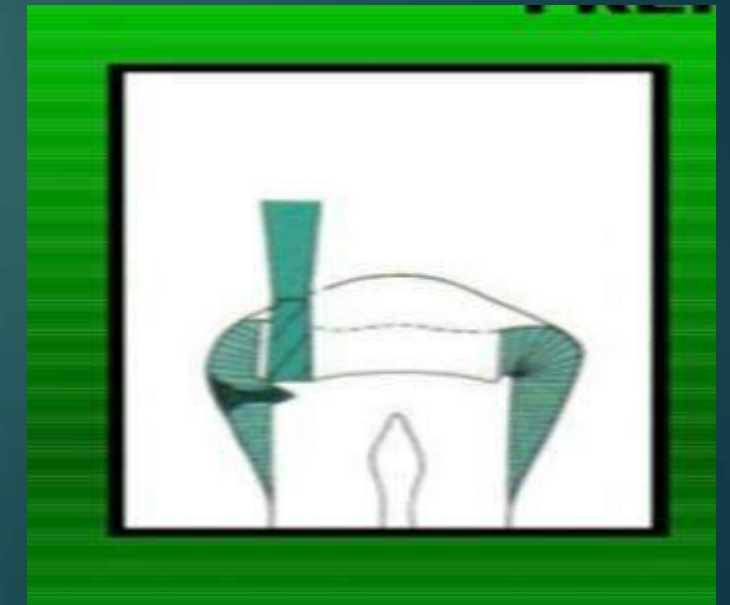
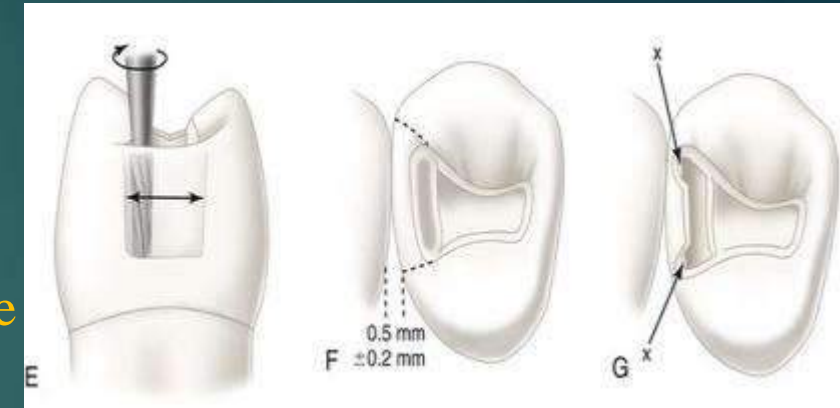
(2) create approximately 90-degree cavosurface margins (i.e., butt-joint margins); and

(3) establish (ideally) not more than 0.5-mm clearance with the adjacent proximal surface facially, lingually, and gingivally.



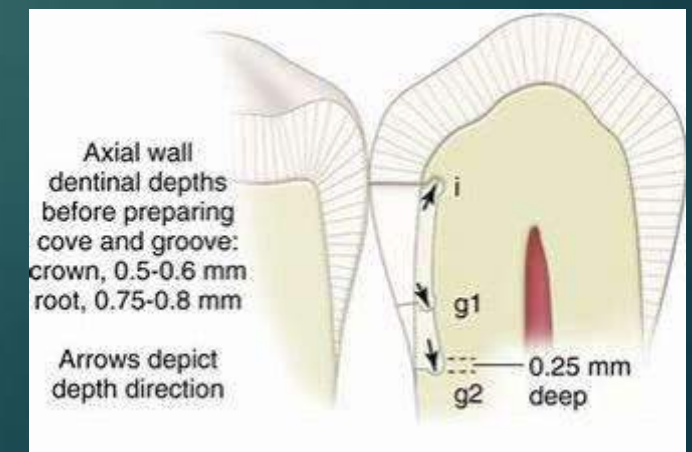
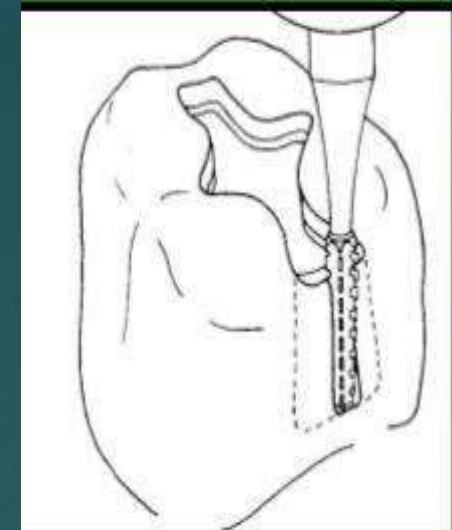
a) STEP 1 - Proximal ditch cut

- The initial procedure in preparing the outline form of the proximal box is the isolation of the proximal (i.e., in this case, mesial) enamel by the proximal ditch cut.
- While maintaining the same orientation of the bur, it is positioned over the DEJ in the pulpal floor next to the remaining mesial marginal ridge.
- The end of the bur is allowed to cut a ditch gingivally along the exposed proximal DEJ, two thirds at the expense of enamel and one third at the expense of dentin.
- The ditch is extended gingivally just beyond the caries lesion or the proximal contact, whichever is greater.



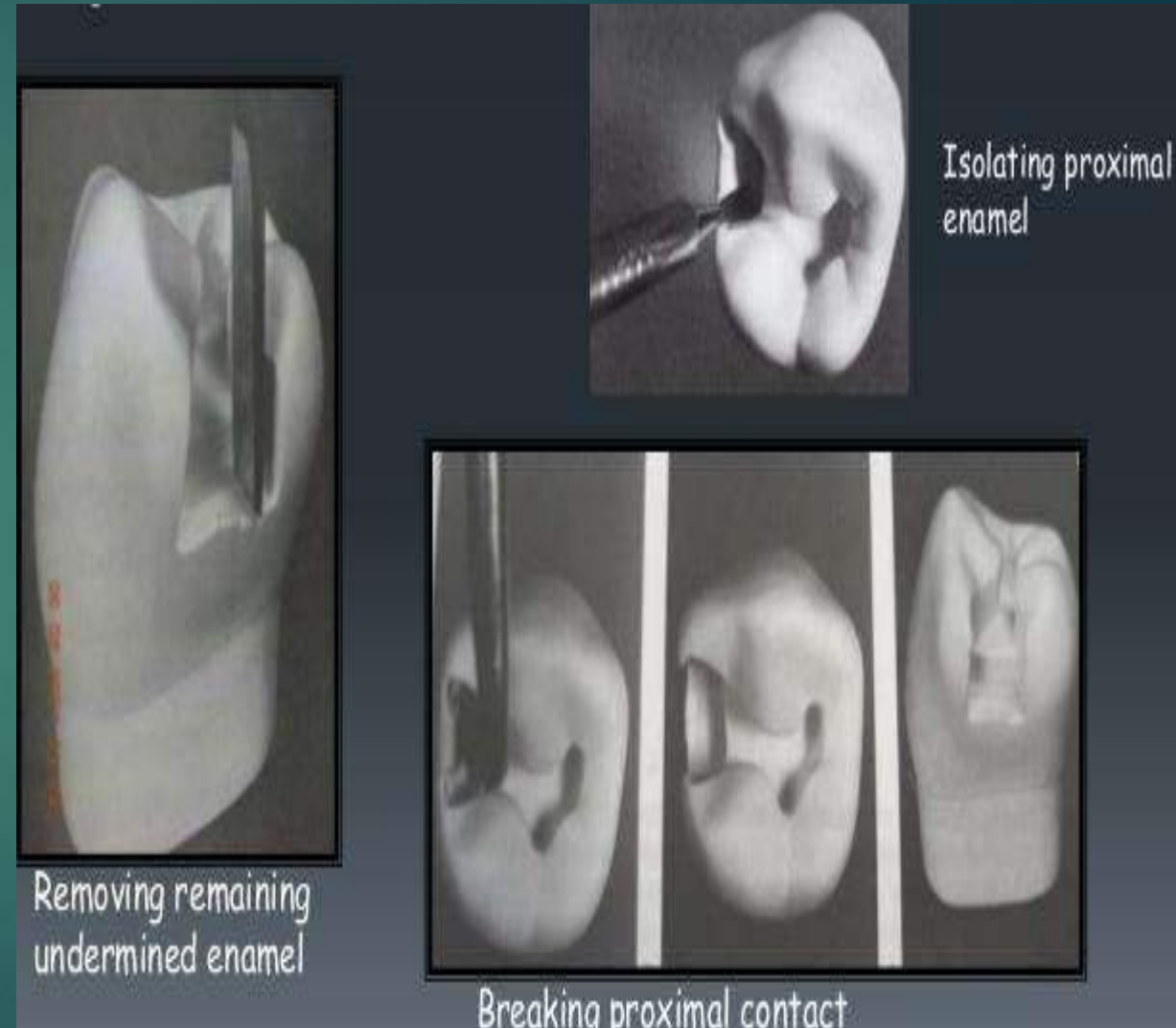
b) Step 2 – Preparation of axial wall

- The harder enamel acts to guide the bur, creating an axial wall that follows the faciolingual contour of the proximal surface and the DEJ .
- The ditch is extended gingivally just beyond the caries or the proximal contact whichever is greater.
- In the tooth crown, the ideal dentinal depth of the axial wall of the proximal boxes of premolars and molars should be the same (two-thirds to three-fourths the diameter of the No. 245 bur [or 0.5–0.6 mm]).
- When the extension places the gingival margin in cementum, the initial pulpal depth of the axiokingival line angle should be 0.7 to 0.8 mm.



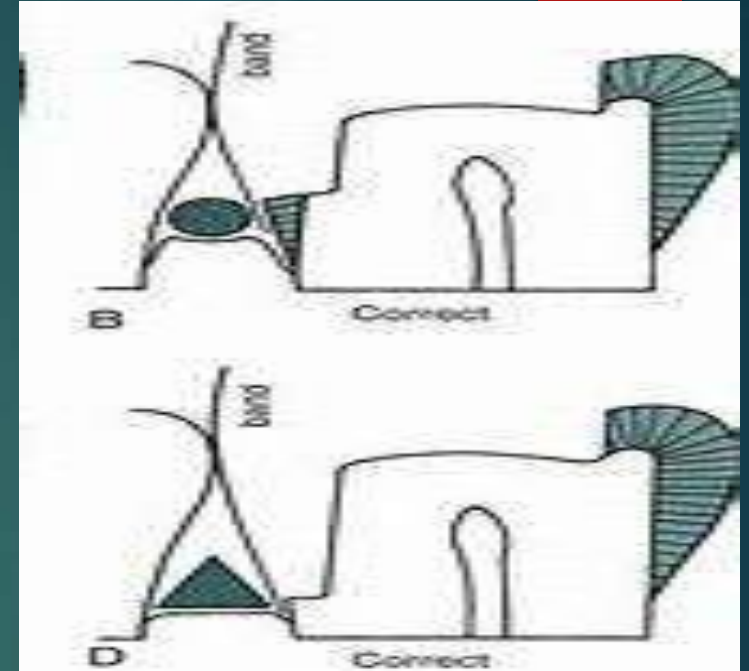
c) Step 3 – Proximal Extension of proximal box

- The proximal extensions are completed when two cuts, one starting at the facial limit of the proximal ditch and the other starting at the lingual limit, extending toward and perpendicular to the proximal surface (until the bur is nearly through enamel at the contact level).
- The side of the bur may emerge slightly through the surface at the level of the gingival floor this weakens the remaining enamel by which the isolated portion is held.



d) **Step 4 - Gingival extension of proximal box.**

- To protect the gingiva and the rubber dam when extending the gingival wall apically, a wooden wedge should already be in place in the gingival embrasure to depress soft tissue.
- When viewed from the occlusal surface the facial and lingual proximal cavosurface margins should be 90 degree.
- The facial and lingual proximal walls should be extended just into the facial and lingual embrasures.



➤ FINAL TOOTH PREPARATION:

I . Removal of any remaining defective enamel and infected carious dentin

Infected carious dentin is removed with a slowly revolving round bur , a discoid type spoon excavator or both be it occlusal step or axial wall in proximal box.

II. Pulp protection

It is achieved in the same way as class I.

III. Secondary resistance and retention form.

- Secondary resistance form

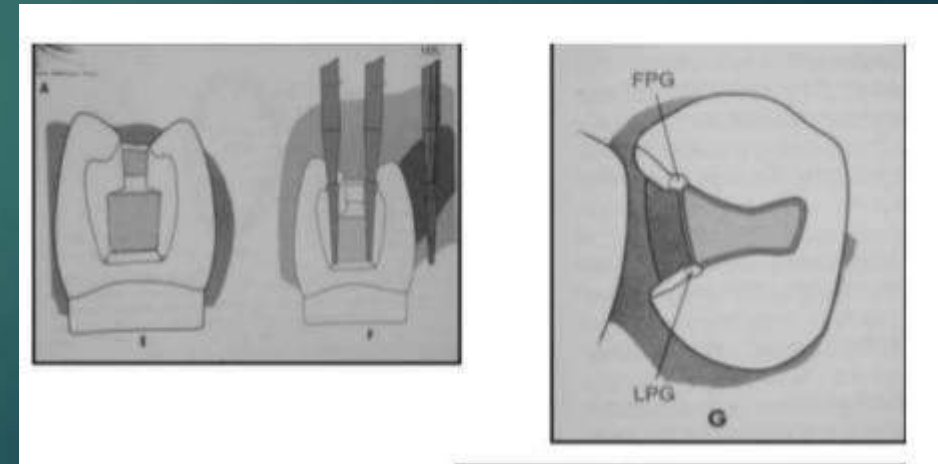
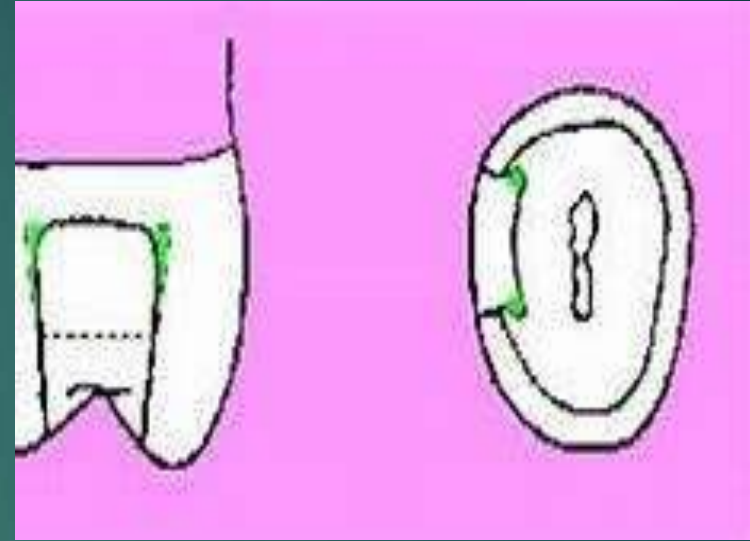
This feature is achieved for class II mainly by the use of **Gingival Marginal Trimmer** which is used for beveling of the gingival seat as well as rounding of axiopulpal line angles.



- Secondary Retention Form

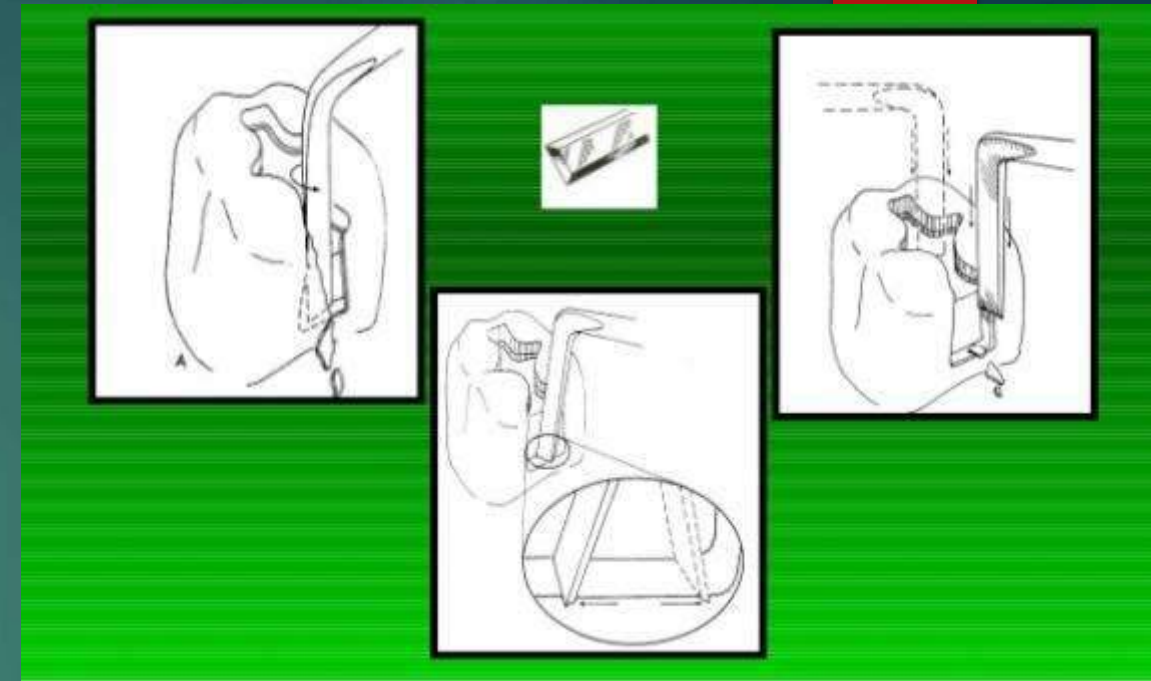
Proximal grooves may be indicated to counter the proximal displacement for which following procedure is followed:

- Use of no. 169 L bur or no.1/4 round bur.
- Placement of bur in the properly positioned axiolingual line angle bisecting it approximately parallel to the DEJ.
- Position the retention groove 0.2mm into the DEJ.
- The bur is tilted to allow cutting to the depth of the diameter of the end of the bur at the end of axiolinguopulpal point angle.
- The similar procedure should be followed for the axiofaciopulpal point angle.



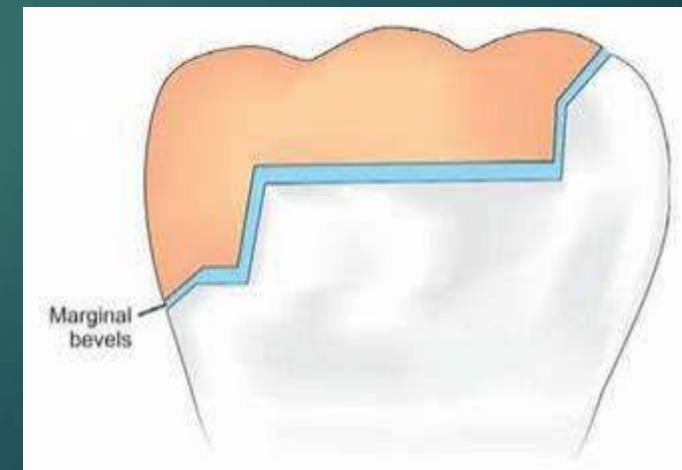
IV. Finishing the external walls.

- The preparation walls and margins should not have unsupported enamel and marginal irregularities.
- The cavosurface angle should be 90 degrees at the proximal margin.
- Use of GMT for the beveling of the gingival margin.



V. Final procedures : cleaning and inspecting

The procedures are carried out similarly to that of class I cavity preparation.



OTHER DESIGNS OF CLASS II CAVITY PREPARATIONS.

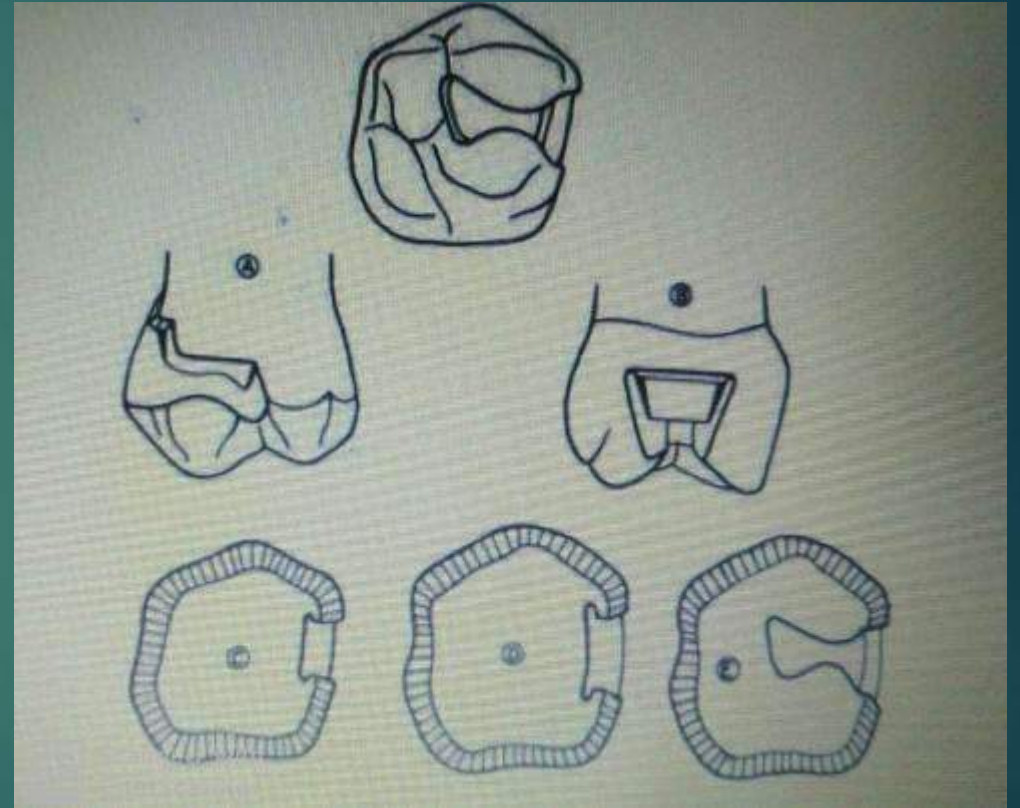
CLASS II DESIGN 1 (CONVENTIONAL DESIGN)

Involvement:

Proximal and occlusal surfaces.

Indications:

- a. A moderate to large size proximal lesion with the occlusal surface of the affected tooth involved in a lesion of similar size.
- b. A proximal lesion undermining an adjacent marginal ridge or not accessible through any other means but involvement of the occlusal surface.
- c. The caries cones occlusally and/or proximally necessitate the cavity width to exceed one-fourth the intercuspal distance.



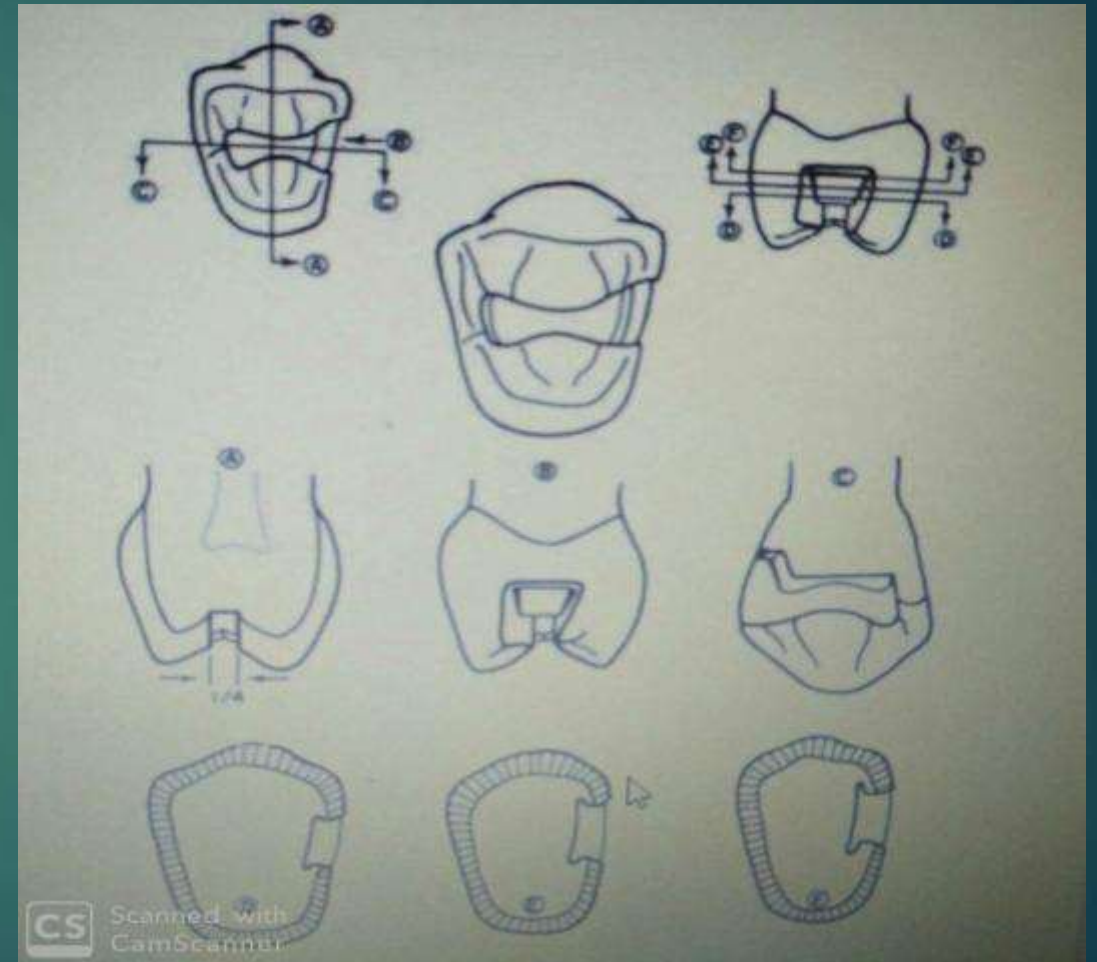
CLASS II DESIGN 2 (MODERN DESIGN)

Involvement:

Proximal and occlusal surfaces.

Indications:

- a) A moderate to small sized proximal lesion i.e., not exceeding the area of near approach.
- b) An occlusal lesion undermining one or both marginal ridges and not exceeding a width of one-fourth the intercuspal distance.



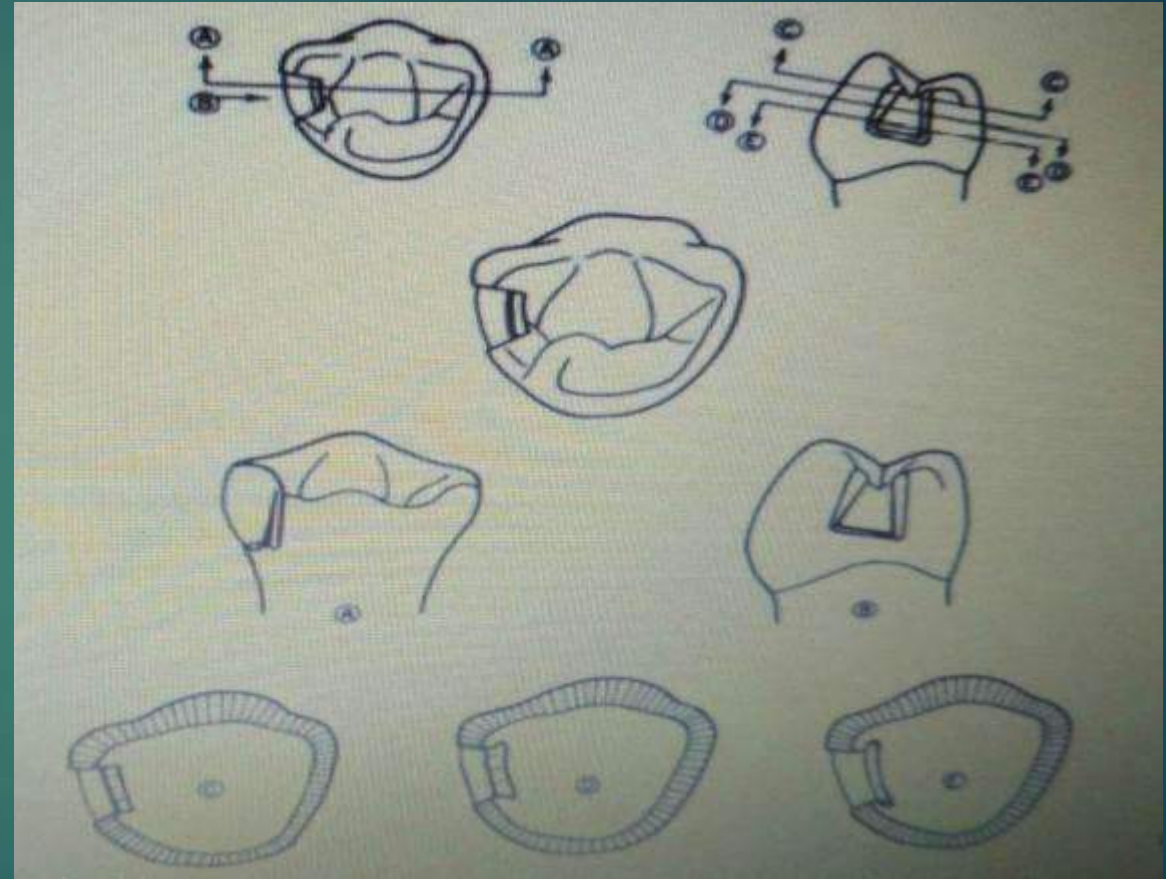
CLASS II DESIGN 3

Involvement:

This preparation is designed to involve primarily the proximal surface and a very limited part of the occlusal surface, not extending beyond the adjacent triangular fossa.

Indications:

- a) There are sound pronounced occlusal crossing ridges, and the inclined planes of the adjacent cusps are smooth and devoid of any crossing fissures.
- b) The decay is restricted to the proximal surface only and the occlusal surface is completely sound.
- c) The restoration is expected to be subjected to minimal loading.

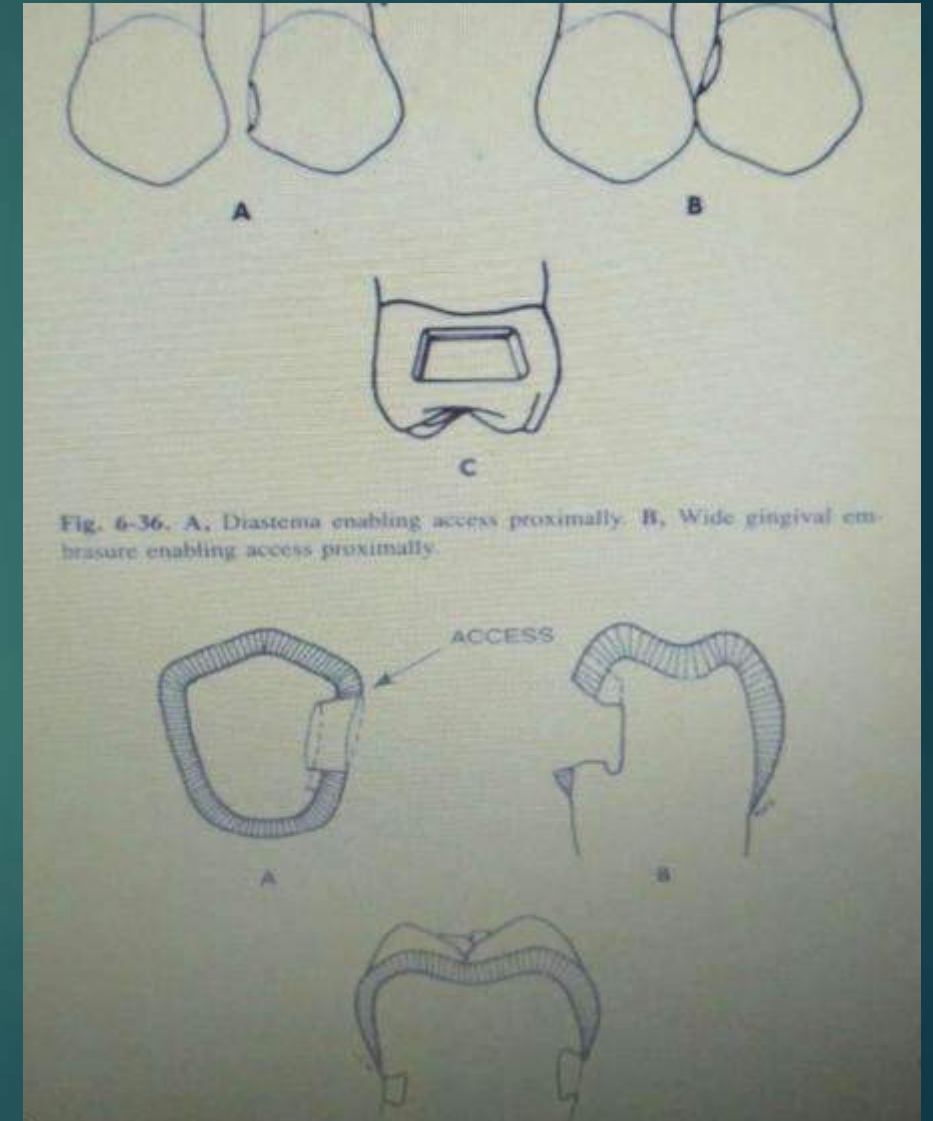


CLASS II DESIGN 4

Involvement: The proximal surfaces only.

Indications :

- a) The decay is restricted to contacting or proximal surfaces without undermining the corresponding marginal ridge.
- b) The proximal lesion is located very gingivally at, or apical to, the cemento-enamel junction, accompanied by gingival recession, making accessibility to the lesion from the facial or lingual direction possible.
- c) There is a diastema or the adjacent tooth is missing facilitating direct access to the lesion. The proximal lesion occurs on tapered teeth with wide gingival embrasures facilitating facial or lingual access to the lesion.



CLASS II DESIGN 5

Involvement:

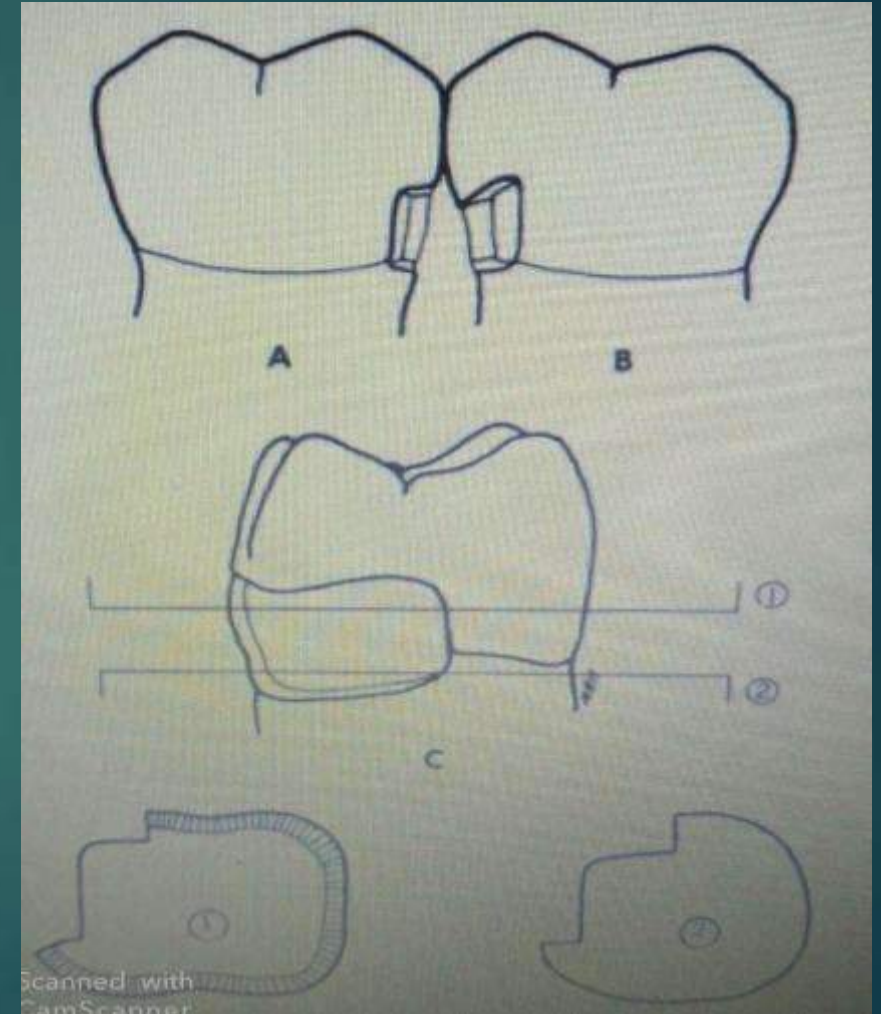
Part of the proximal surface, with a very limited access area on the facial or lingual surface.

Indications:

There are two shapes for this design, each with certain indications. In shape A the facial or lingual access will not have a dovetail form. The indications for this design are:

- The cavity, when completed, will have four definite surrounding walls, with opposing retentive grooves in at least two of them.
- The marginal ridge is intact and adequately supported apically and occlusally with bulky tooth structure.
- The lesion does not involve the contact area, nor does it undermine enamel in the contact area.
- The gingival embrasure is not accessible, exposed or pronounced enough to facilitate proximal instrumentation without cutting a facial or lingual access cavity.

In shape B the facial or lingual access will have a locking feature in the form of a dovetail, unilaterally cut in the occlusal direction.



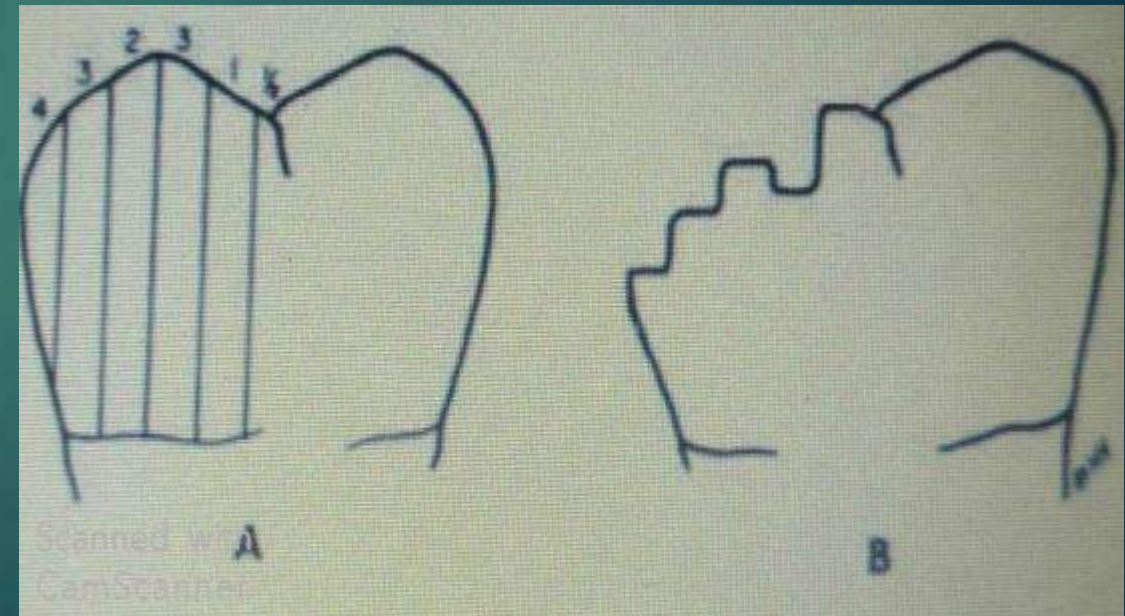
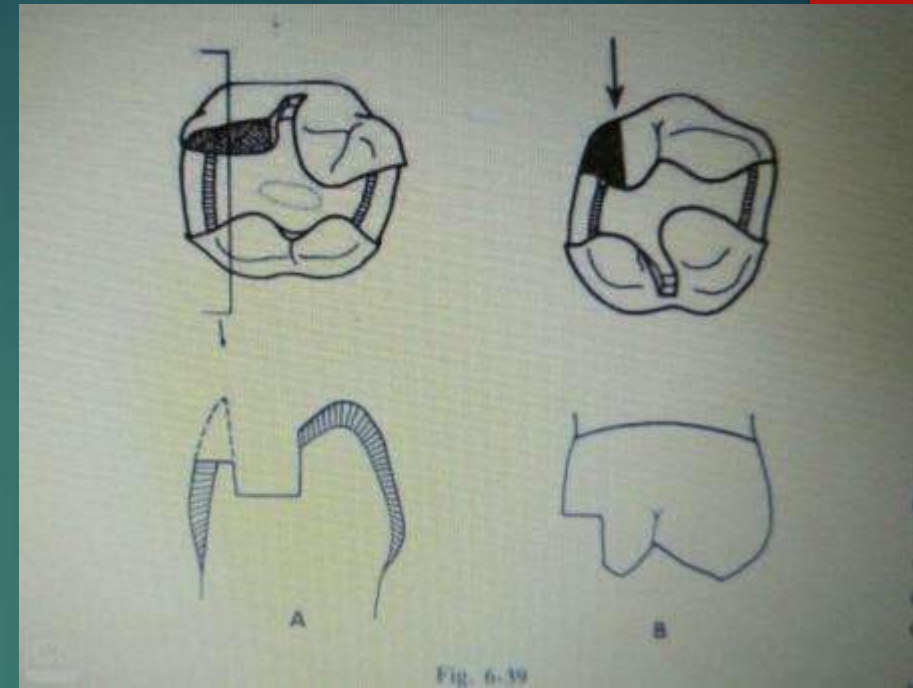
CLASS II DESIGN 6

Involvement:

The occlusal, proximal and part of the facial and/or lingual surfaces.

Indications:

- a) The cusp length is double or more its width, either throughout or at certain portions of the cusp.
- b) A cusp is completely missing or undermined.
- c) A foundation for cast restoration is required.
- d) Teeth have a doubtful prognosis endodontically and periodontally.
- e) A badly broken down tooth needs to be prepared prior to endodontic or orthodontic treatment.
- f) A cast restoration is not indicated.



CLASS II DESIGN 7 (combination of class II and class v)

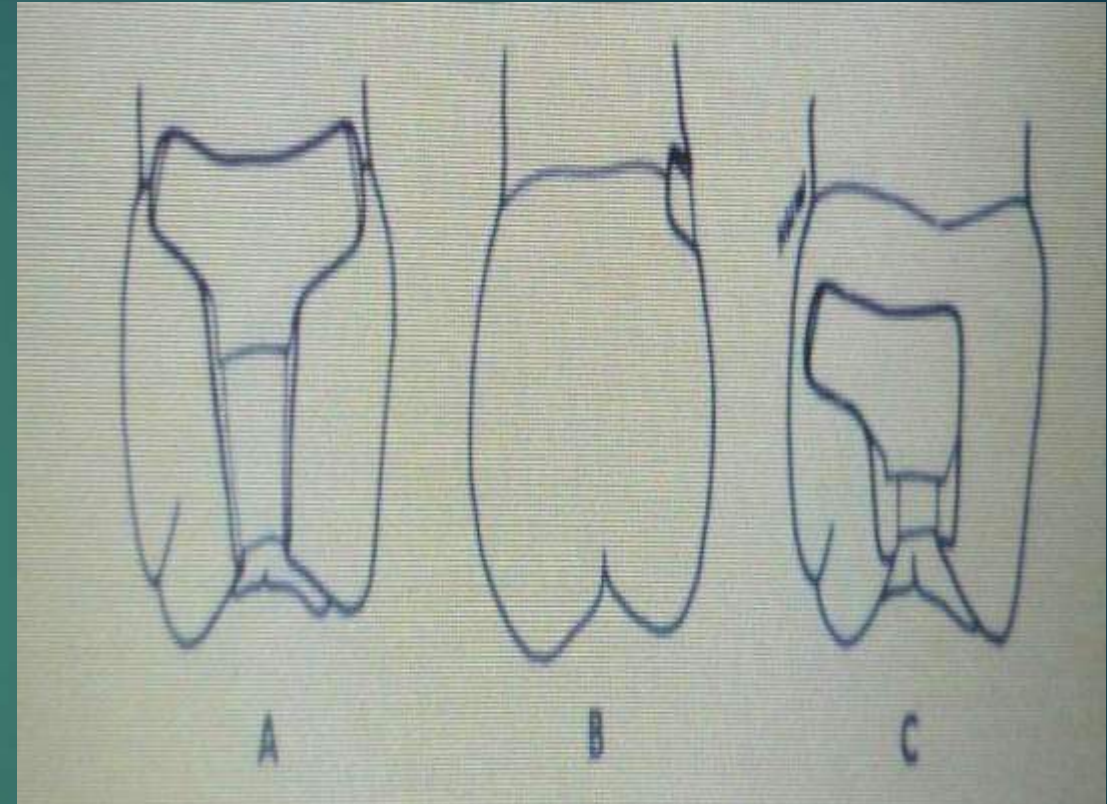
Shape A: The junction between the Class II and Class V via the proximal, crossing the axial angle.

Involvement:

The occlusal, proximal, and part or all of the gingival third of the facial and/or lingual surfaces with the intervening part of the axial angle.

Indications:

This design is indicated when at a location apical to the contact area, an occluso-proximal lesion joins a senile decay lesion via decalcification, or a defect that has spread laterally beyond the lateral limit of the original occluso-proximal lesion and the regular cavity preparation.



Shape B: The junction between the Class I and Class V is through the occlusal via the buccal and/or lingual grooves.

Involvement: The proximal, occlusal, facial and/or lingual surfaces.

Indications:

- a) A Class V lesion connects with an occluso-proximal lesion via a facial or lingual fissured groove.
- b) Surface defects or decalcifications on the facial or lingual surface connect a Class V lesion with an occluso-proximal lesion.

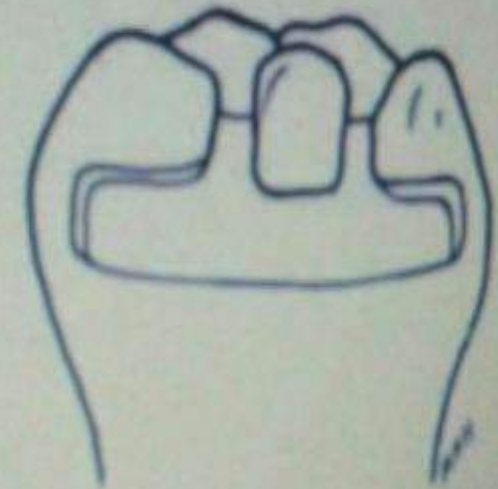

Fig. 6-42

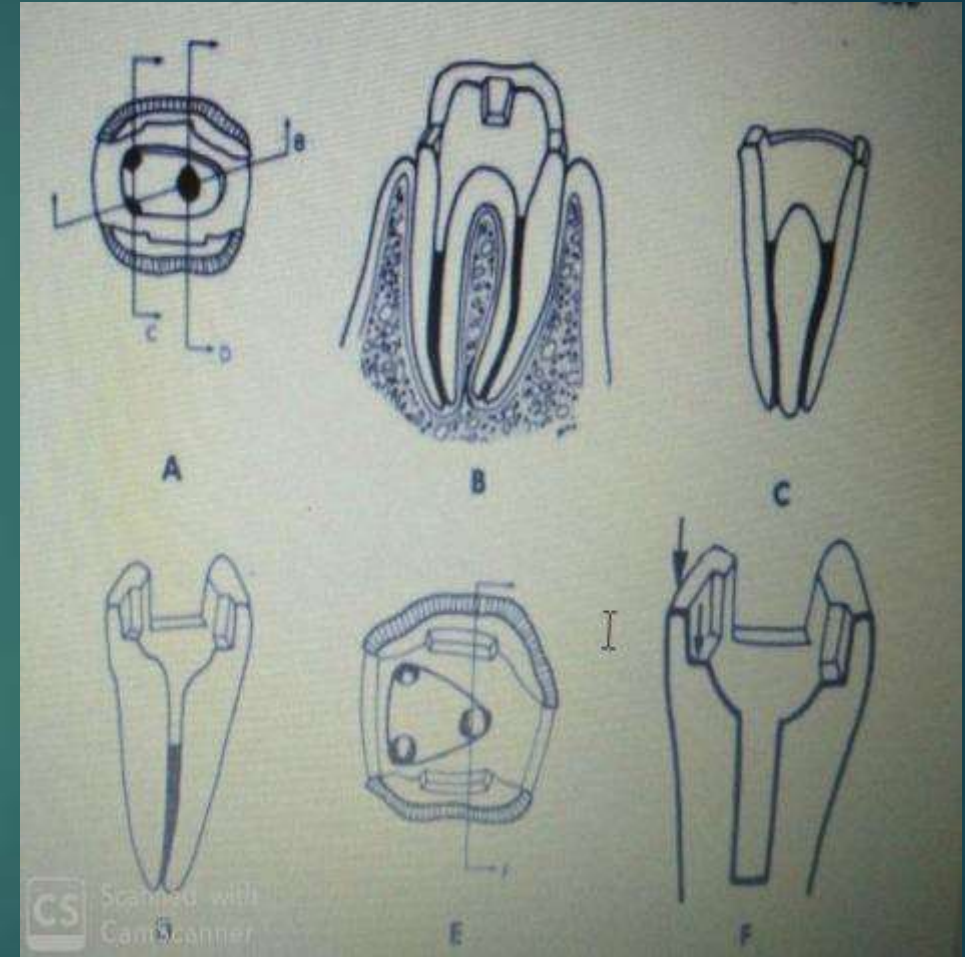
CLASS II DESIGN 8

Involvement:

Two or more surfaces of an endodontically treated tooth that does not require post retention.

Indications:

- a) The tooth has a sufficient pulp chamber to accommodate retaining, self-resisting amalgam bulk.
- b) The post-endodontic pulp chamber has at least two opposing intact walls.
- c) The tooth contains sufficiently large root canals to accommodate retaining, resisting amalgam bulk at its (their) occlusal one-thirds.
- d) There is sufficient remaining tooth structure to permit the preparation of flat planes at right angles to occluding forces.
- e) There has been successful root canal therapy leaving an intact subpulpal floor.
- f) The tooth does not show any signs of cracking or crazing.



RESTORATIVE TECHNIQUE FOR CLASS II AMALGAM PREPARATION

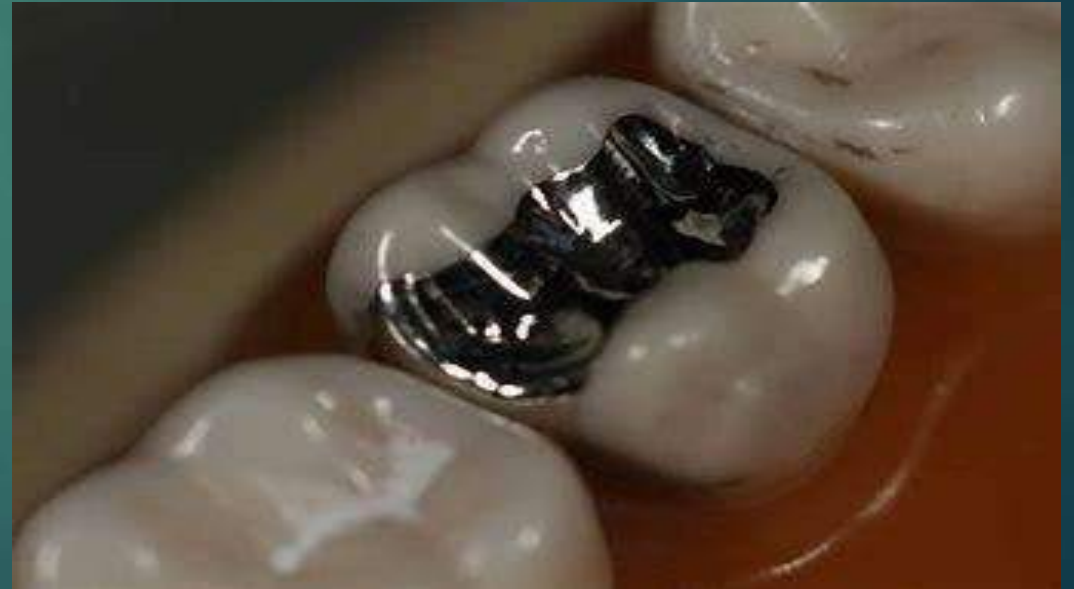a) Desensitizer placement

A dentin desensitizer is placed on the prepared tooth structure per manufacturer instructions. Excess moisture is removed without desiccating the dentin.

b) Matrix Placement

The primary function of the matrix is to enable proper restoration of anatomic contours and contact areas. The qualities of a good matrix include

- 1) rigidity,
- 2) establishment of proper anatomic contour,
- 3) restoration of correct proximal contact relationships,
- 4) prevention of gingival excess,
- 5) convenient application, and
- 6) ease of removal

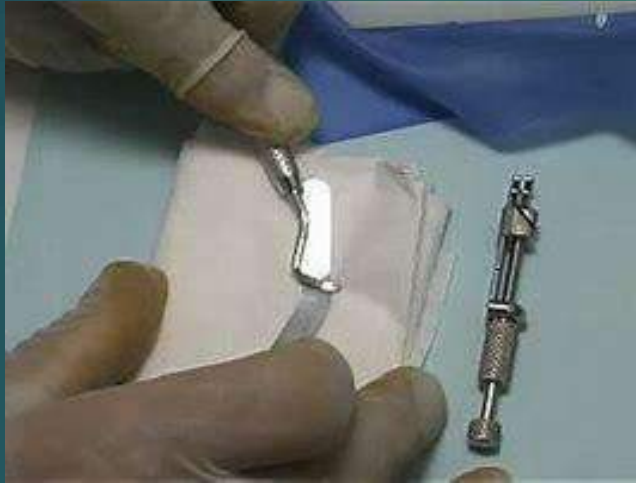

UNIVERSAL MATRIX

- The universal matrix system (designed by B.R. Tofflemire) is ideally indicated when three surfaces (i.e., mesial, occlusal, distal) of a posterior tooth have been prepared.
- A definite advantage of the Tofflemire matrix retainer is that it may be positioned on the facial or lingual aspect of the tooth. However, lingual positioning requires the contra-angled design of the retainer.
- It has a retainer and a band which on placement remain stable.



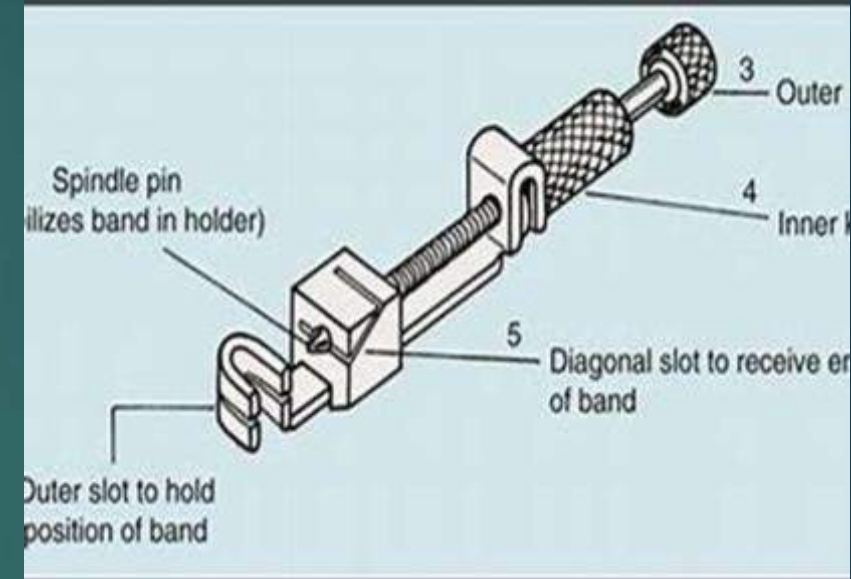
- The universal matrix band itself does not meet all the requirements of an ideal matrix band. The conventional, universal matrix band must be shaped (i.e., burnished) to reproduce natural anatomic contour and resultant proximal contact.
- Uncontoured bands are available in two thicknesses, 0.05 mm and 0.038 mm.



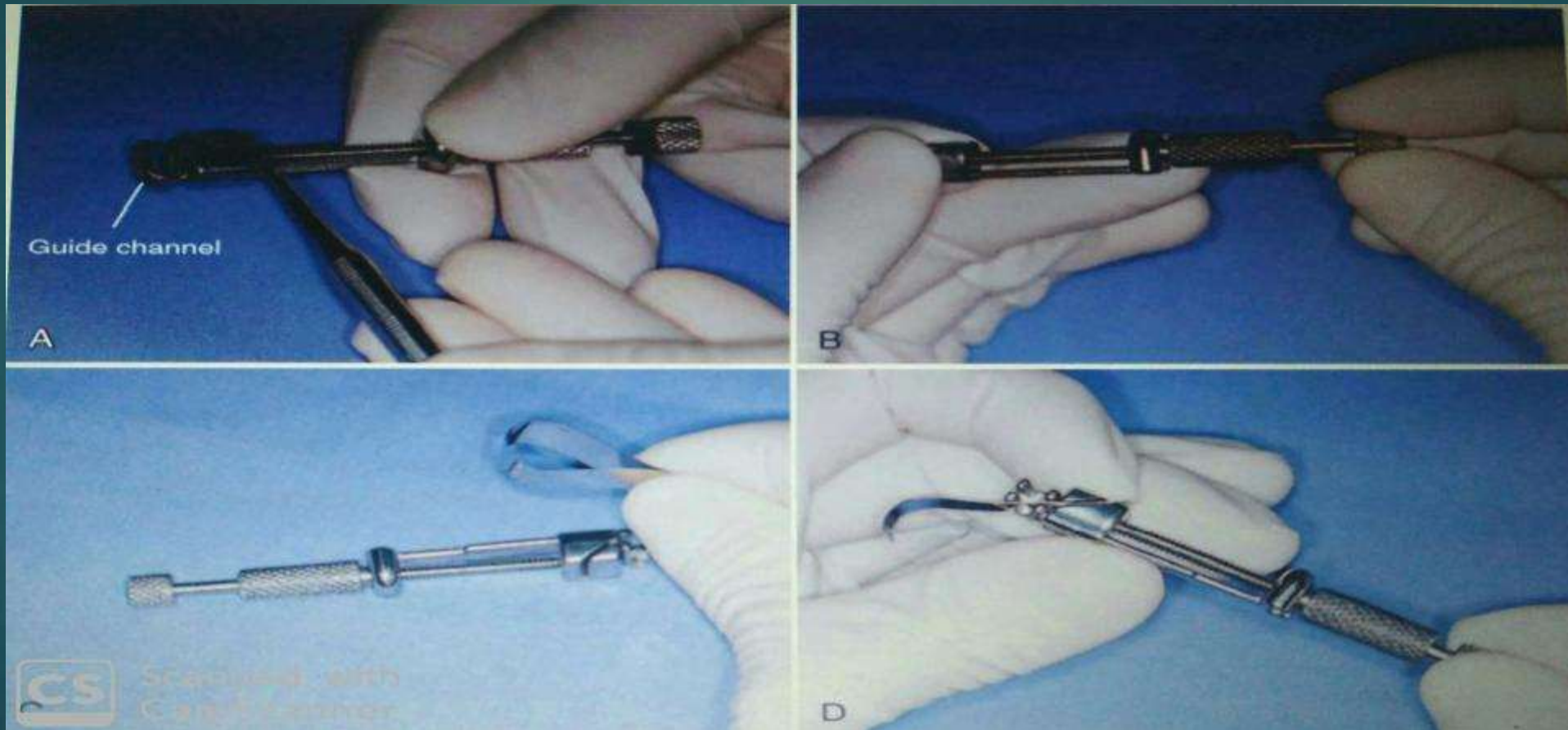
- Precontoured matrix bands are also available which do not require burnishing.

Placement:

- To prepare the retainer to receive the band, the larger of the knurled nuts is turned counterclockwise until the locking vise is positioned adjacent to the guide channel on the end of the retainer.
- While holding the large nut, turn the smaller knurled nut counterclockwise until the pointed spindle is free of the slot in the locking vise.
- The matrix band is folded end to end, forming a loop, and placed according to the circumference of the tooth.
- The band is positioned in the retainer so that the slotted side of the retainer is directed gingivally.



- The two ends of the band are placed in the slot of the locking vice so that the ends are aligned with the edge of the vice, and the smaller of the knurled nuts is turned clockwise to tighten the pointed spindle against the band within the locking vice.

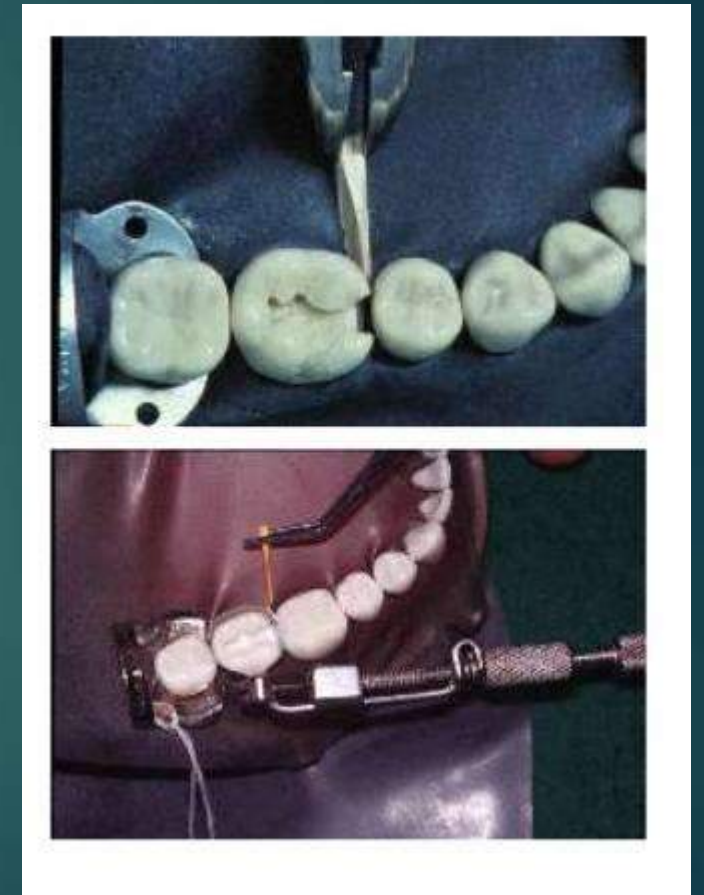

- Once the matrix band is in place, the larger knurled nut is rotated clockwise to tighten the band slightly.
- When the band is correctly positioned, the band is securely tightened around the tooth.
- Ideally the band should be positioned 1 mm apical to the gingival margin or deep enough to be engaged by the wedge (whichever is less) and 1 to 2 mm above the adjacent marginal ridge to allow for adequate condensation of the amalgam in the marginal ridge areas.

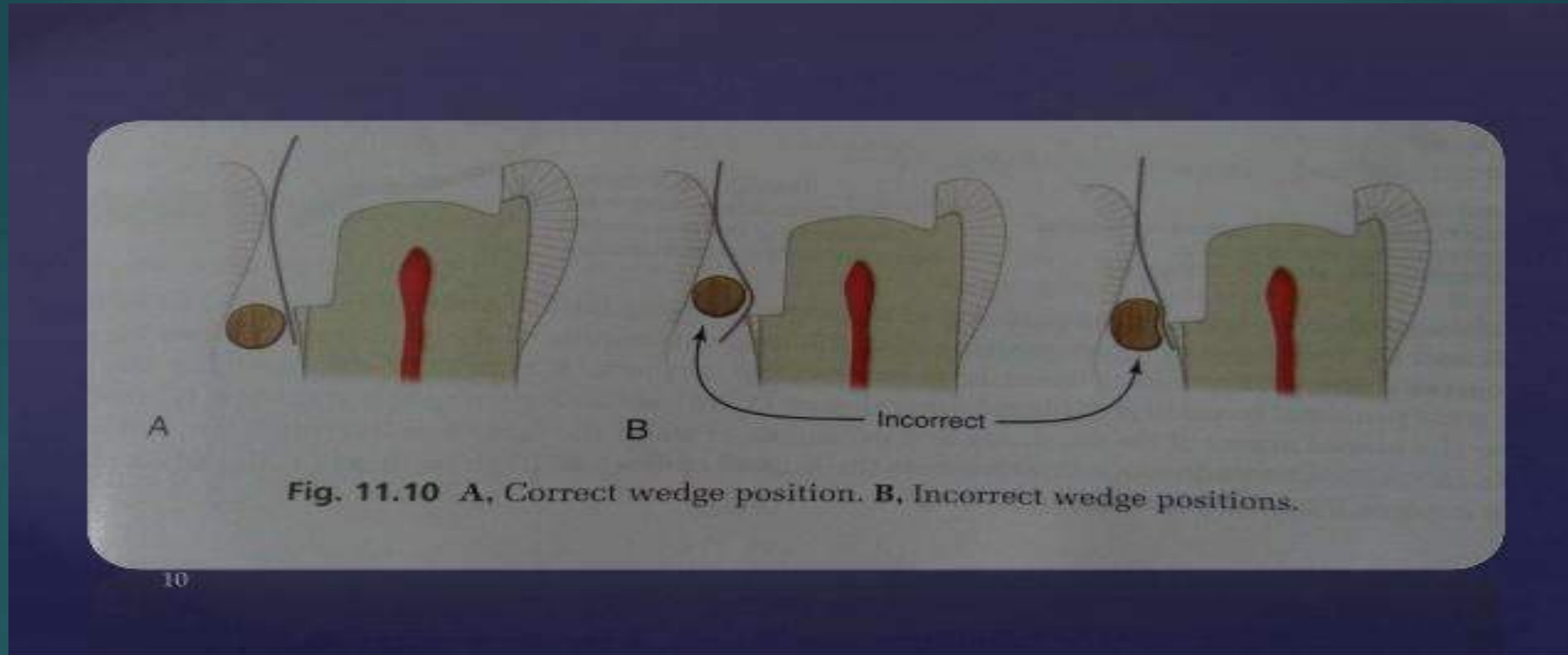


- After the matrix contour and extension are evaluated, a wedge is placed in the gingival embrasure(s) using the following technique:

- 1) break of approximately 1.2 cm of a round toothpick.
- 2) grasp the broken end of the wedge with the No. 110 pliers.
- 3) insert the pointed tip from the lingual or facial embrasure (whichever is larger), slightly gingival to the gingival margin; and
- 4) wedge the band tightly against the tooth and margin , the wedge may be lightly moistened with water or a water-soluble lubricant to facilitate its placement.



- The wedge placement should be proper so as to avoid any faulty restoration as shown below.

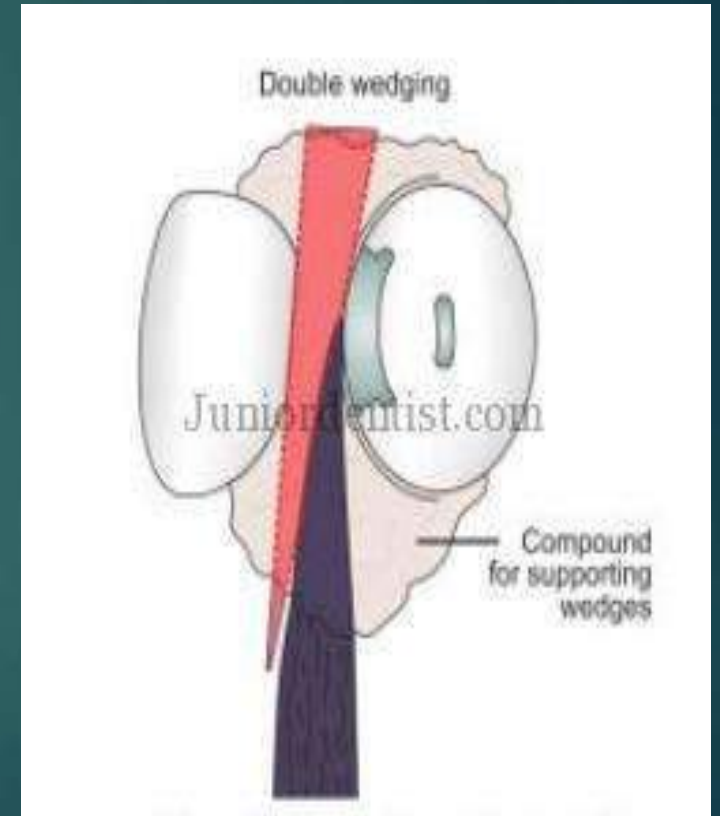


- The band should be tight enough that it does not move, slight movement may lead to overhanging restorations that can cause plaque accumulation and secondary caries.

There are different techniques of wedging that are considered according to the tooth structure and adjacent structures:

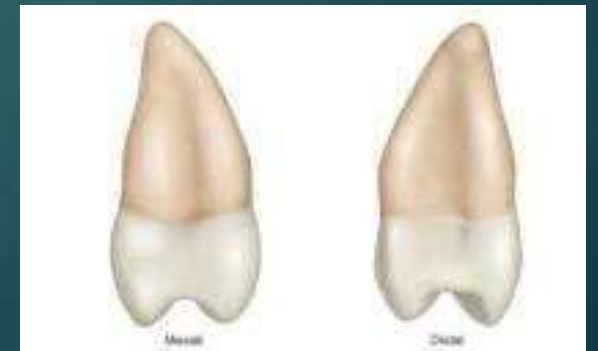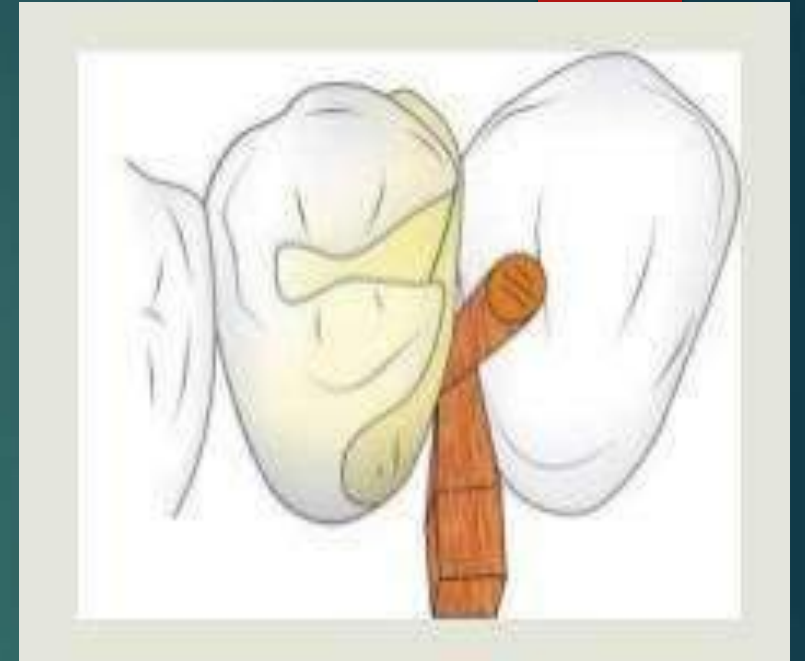
1) Double Wedging Technique:

- Double wedging refers to using two wedges: one from the lingual embrasure and one from the facial embrasure.
- Two wedges help ensure that the gingival corners of *a wide proximal box* may be properly condensed; they also help minimize gingival excess.
- Double wedging should be used only if the middle two thirds of the proximal margins are not able to be adequately wedged.



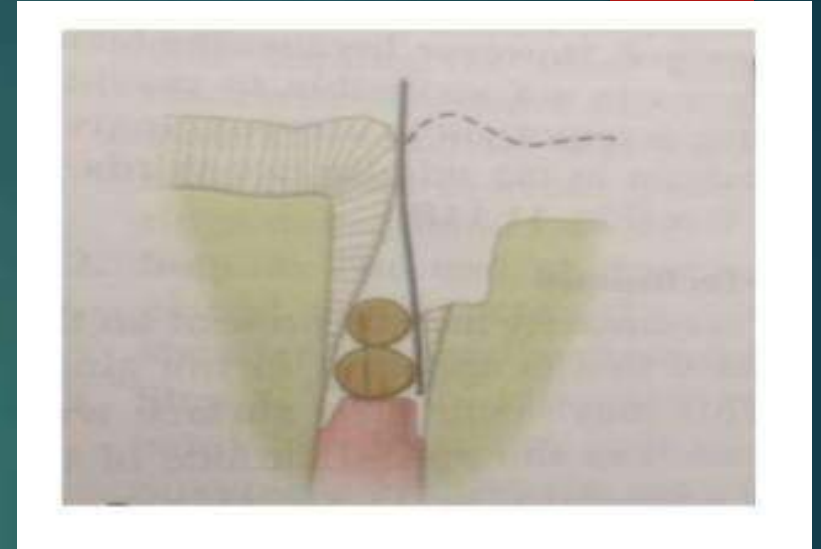
Wedge wedging technique:

- Occasionally a concavity may be present on the proximal surface that is adjacent to the gingival margin. This may occur on a surface with a fluted root, such as the mesial surface of the maxillary first premolar.
- A gingival margin located in this area may be concave. To wedge a matrix band tightly against such a margin, a second pointed wedge may be inserted between the first wedge and the band at a right angle to the first wedge.



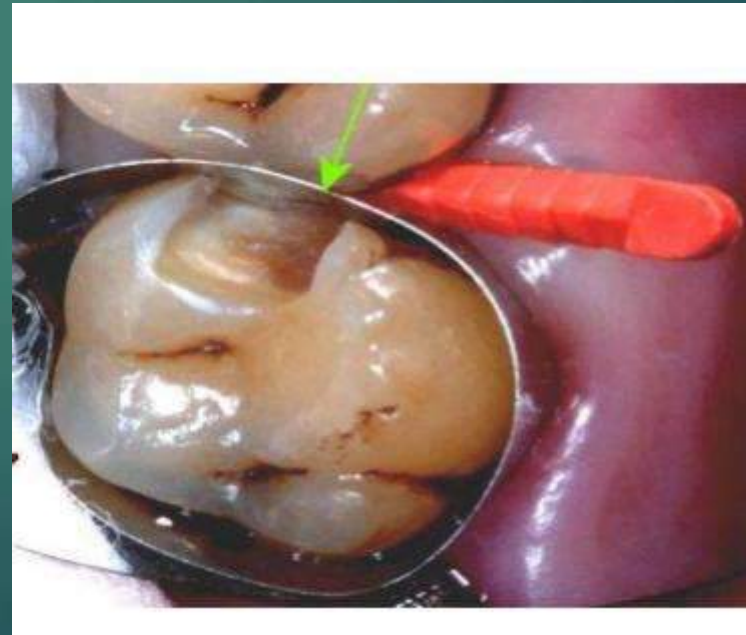
Piggy back wedging technique:

- Used in patients with gingival recession.
- The wedge is significantly apical to the gingival margin so a second wedge is placed above the first one.

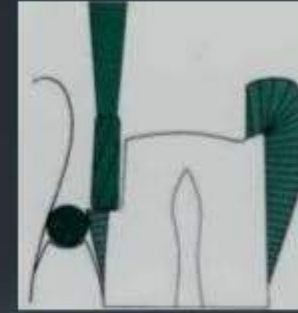


Single Wedging Technique:


- It is technique where single wedge is placed.



- The triangular (i.e. anatomic) wedge is recommended for a preparation with a deep gingival margin.
- The triangular wedge is positioned similarly to the round wedge, and the goal is the same.
- When the gingival margin is deep (cervically), the base of the triangular wedge more readily engages the tooth gingival to the margin without causing excessive soft tissue displacement.



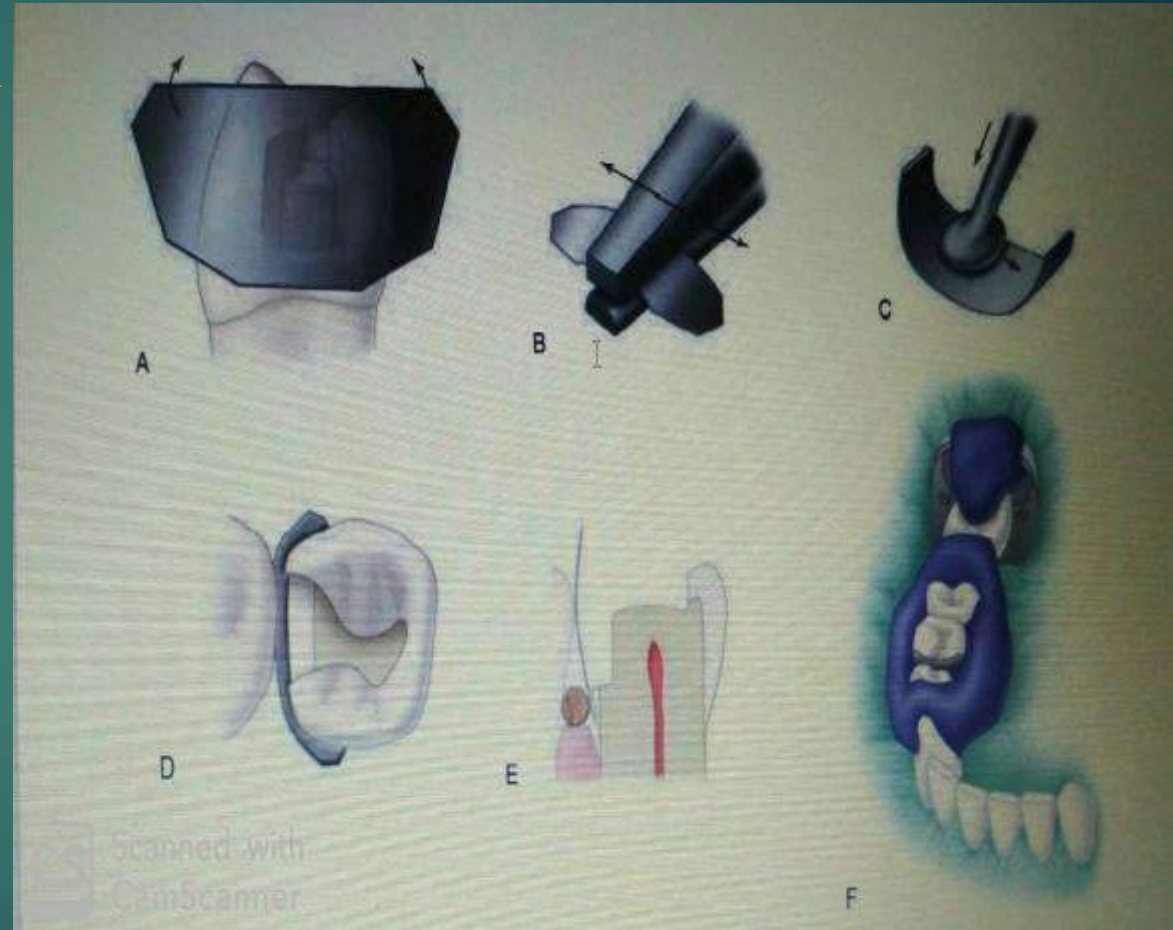Rounded
toothpick wedge



Triangular wedge
Indicated in deep
Gingival
extension

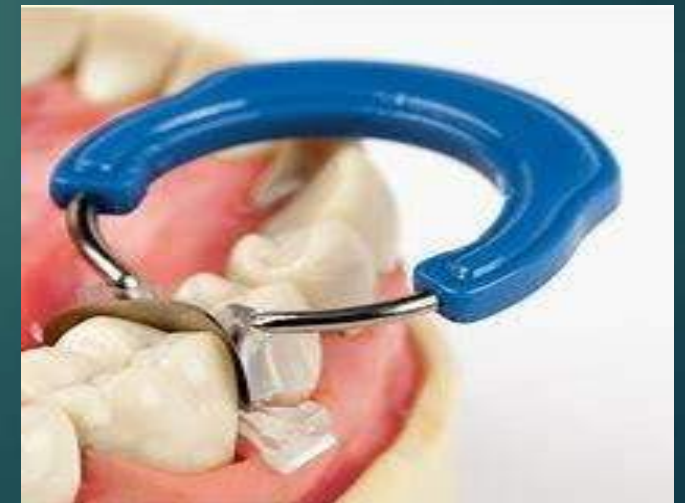RIGID MATERIAL SUPPORTED SECTIONAL MATRIX

- An alternative to the universal matrix is the use of a properly contoured sectional matrix that is wedged and supported by a material that is rigid enough to resist condensation pressure.
- The supporting material selected must be easy to place and to remove.
- Examples include light-cured, thermoplastic and quick-setting rigid polyvinyl siloxane (PVS) materials.



PRECONTOURED MATRIX STRIPS

- Commercially available sectional metal strips (e.g., Palodent System; DENTSPLY, Milford, Garrison) are precontoured and ready for application to the tooth.
- It delivers easy, predictable and accurate contact creation by utilizing advance ring, matrix and wedge technology.
- The contact area of the adjacent tooth occasionally is too close to allow placement of the contoured Palodent strip without causing a dent in the strip's contact area, making it unusable



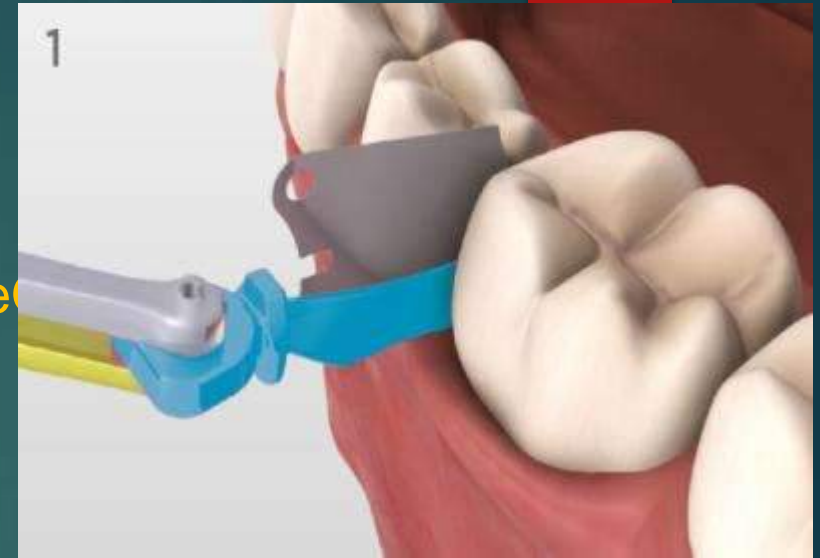1. Strong Ni-Ti Rings for outstanding spring strength and memory.
2. Glass-fiber reinforced plastic tines are V-shaped to accommodate the wedge.
3. Pin tweezer hole for easy placement & removal of wedge
4. Top tab for easy insertion and side tab for removal of matrix
5. Gingival apron to prevent gaps in gingival-axial corner
6. Greater curvature: matrix wraps around tooth
7. Pronounced marginal ridge for natural-looking anatomy



PROCEDURE:

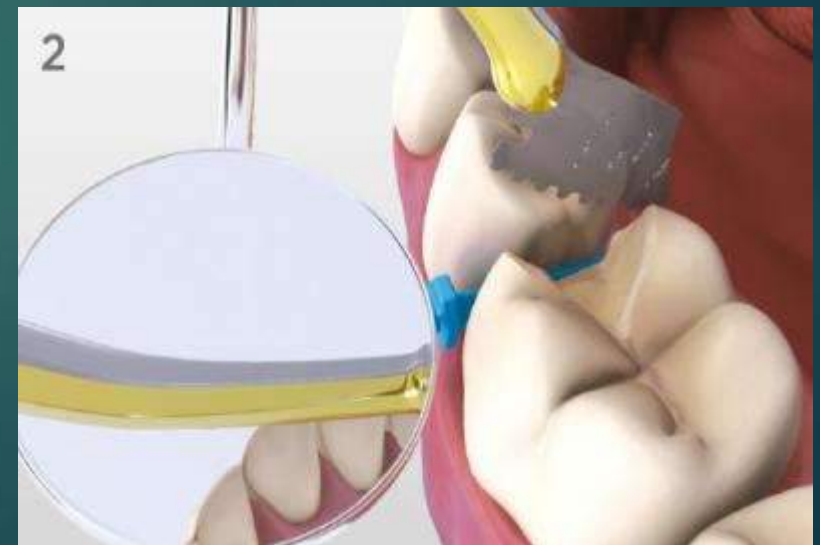STEP 1:

Using the Pin-Tweezers, place a Palodent Plus Wedge or WedgeGuard firmly from the lingual or buccal side and proceed with prep.



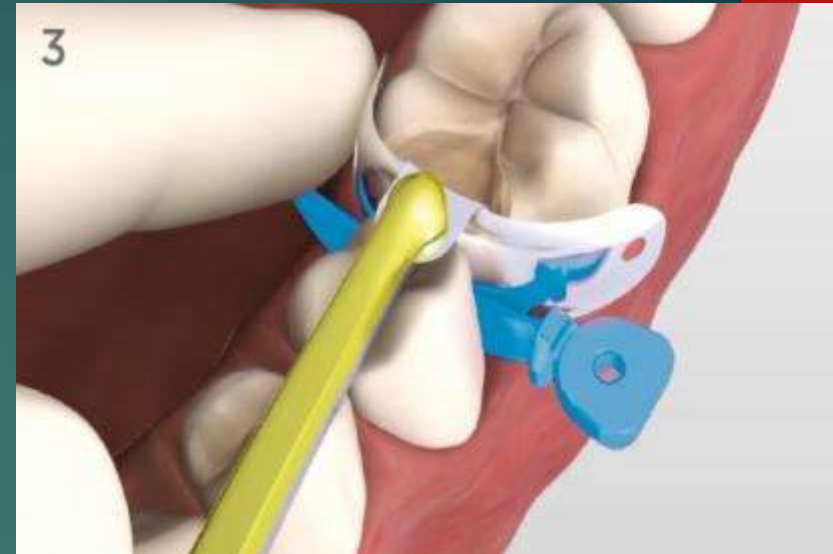
STEP 2:

After prep, if using Palodent WedgeGuard, support Wedge with mirror or dental instrument while using Pin Tweezers to detach the shield.



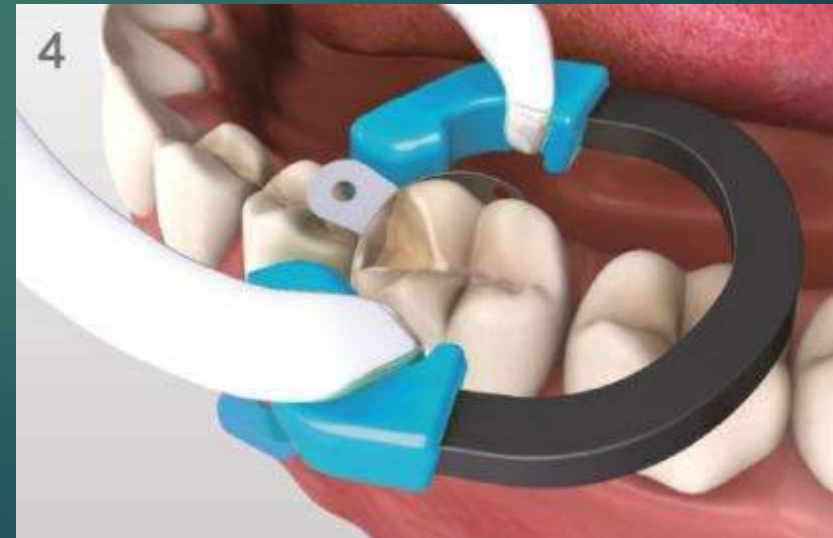
STEP 3:

Place Palodent Plus Matrix with Pin Tweezers.



STEP 4:

Place the Palodent Plus Ring on top of the wedge to provide separation.



AUTOMATRIX

- The automatrix is a *retainerless matrix system* designed for any tooth regardless of its circumference and height.

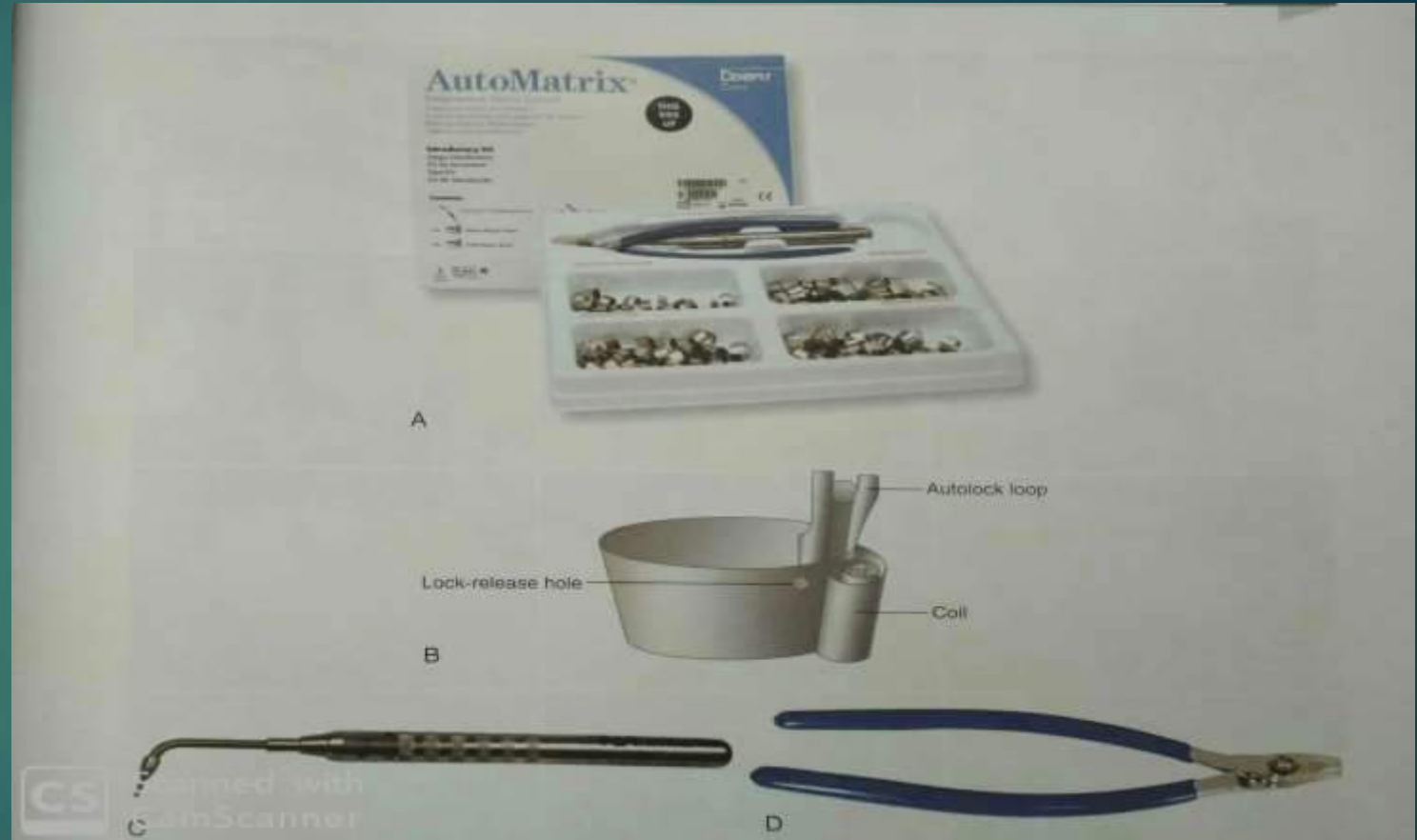- The automatrix bands are supplied in three widths:
 - 1) 3/16 inch (4.8mm) 0.002 - inch thickness.
 - 2) 1/4 inch (6.35mm) 0.002 - inch thickness and 0.0015 inch thickness.
 - 3) 5/16 inch (7.79mm) 0.002- inch thickness.

A – Automatrix retainerless matrix system.

B- Automatrix band

C- Automatrix II tightening device

D- Shielded nippers



A - Tooth preparation with wedges in place.

B - Enlarge circumference of band if necessary.

C - Burnish band with egg-shaped burnisher.

D-F - Place band around tooth, tighten with Automate II tightening device, and set wedges firmly in place.

G - Apply green compound.

H - Contour band with back of warm Black spoon excavator.

I - Overfill preparation, and carve the occlusal aspect.

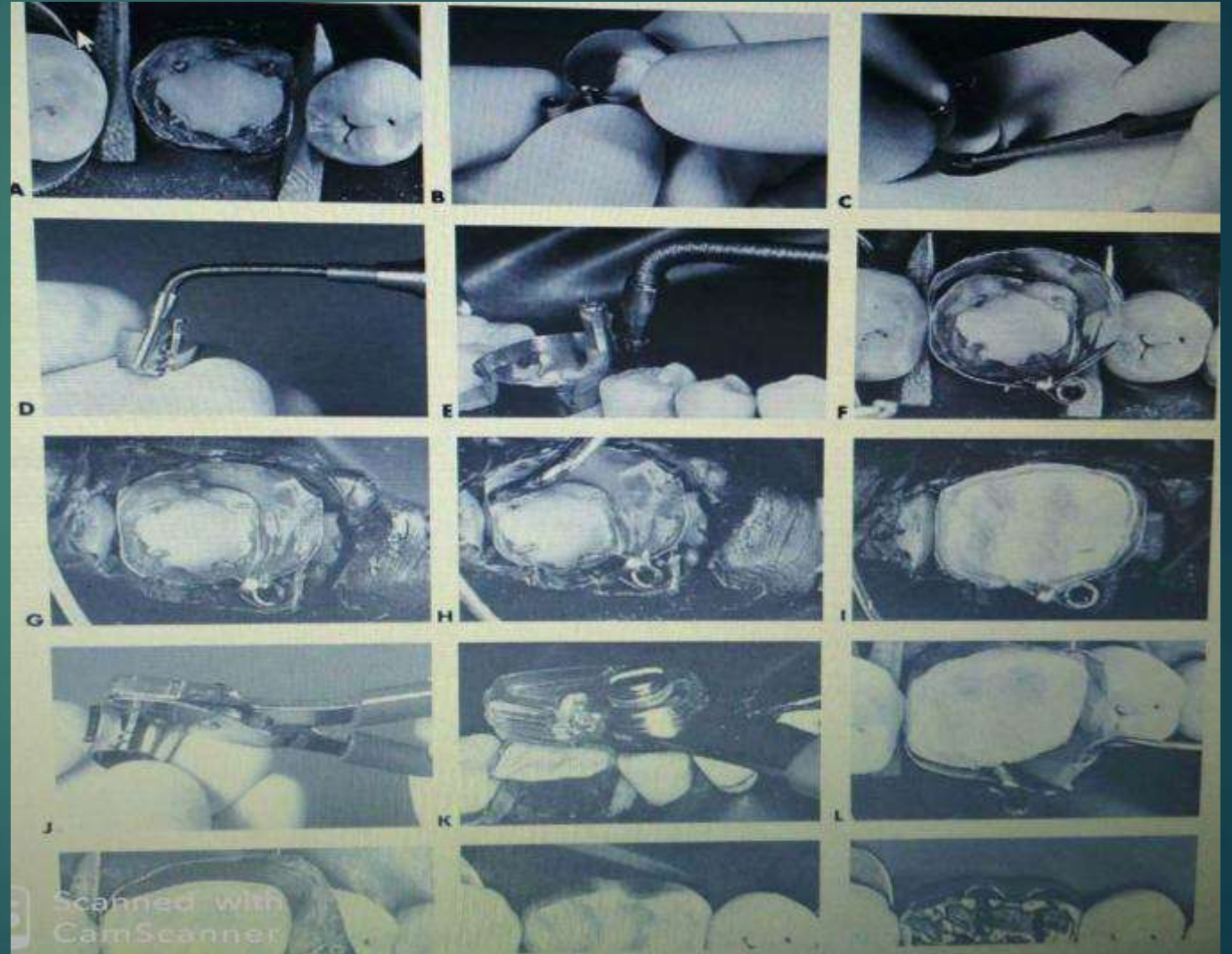J&K- Use shielded nippers to cut autolock loop.

L - Separate band with explorer.

M - Remove band in oblique direction.

N - Restoration carved.

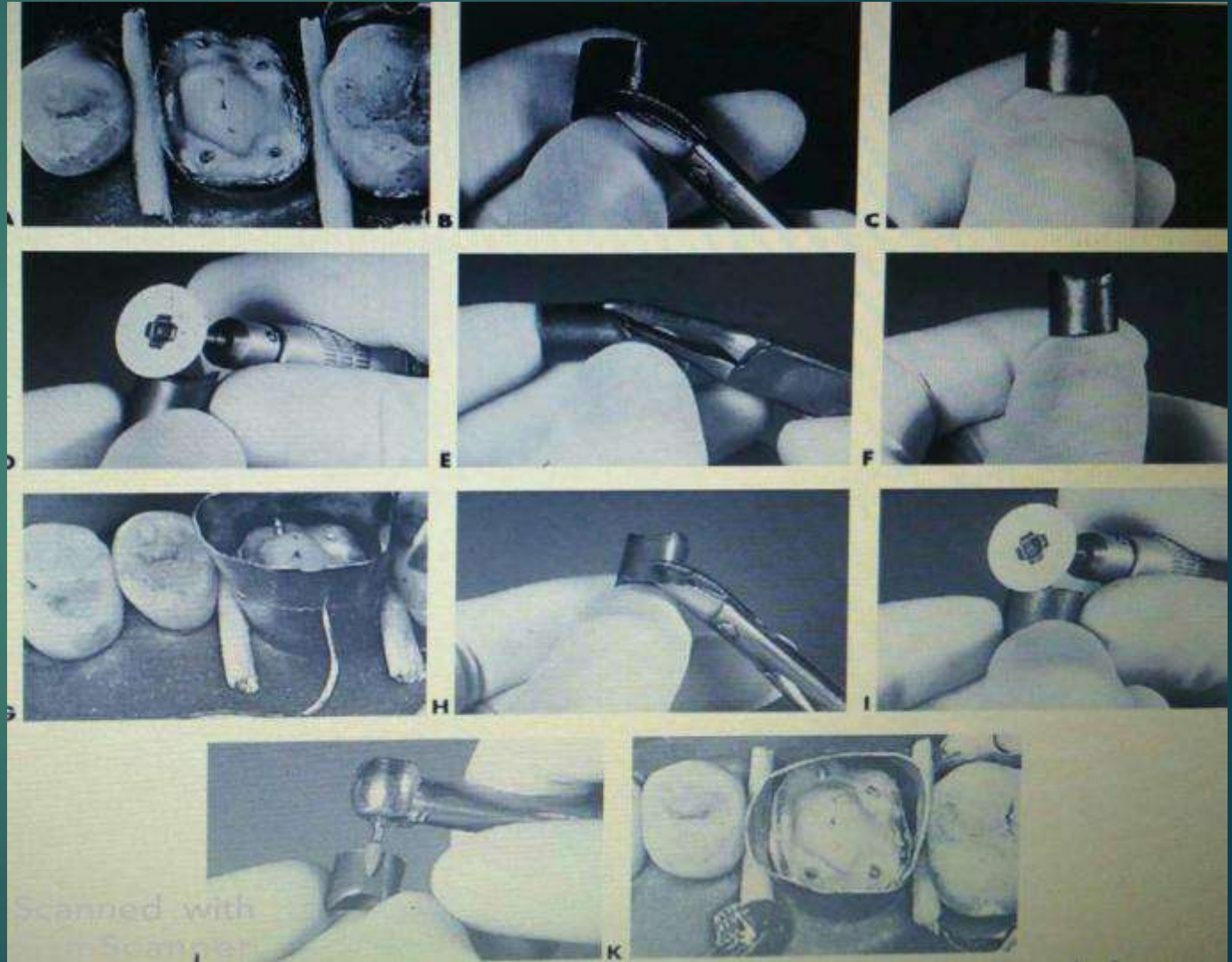O - Restoration polished.



Compound-Supported Copper Band Matrix.

- The compound-supported copper band matrix may be used when the Tofflemire matrix cannot be used successfully.
- Fabrication of the copper band matrix can be time-consuming, but when done properly satisfies the requirements of a good matrix.
- Select the smallest copper band that fits over the circumference of the tooth, but still touches or nearly touches the proximal surfaces of the adjacent teeth.

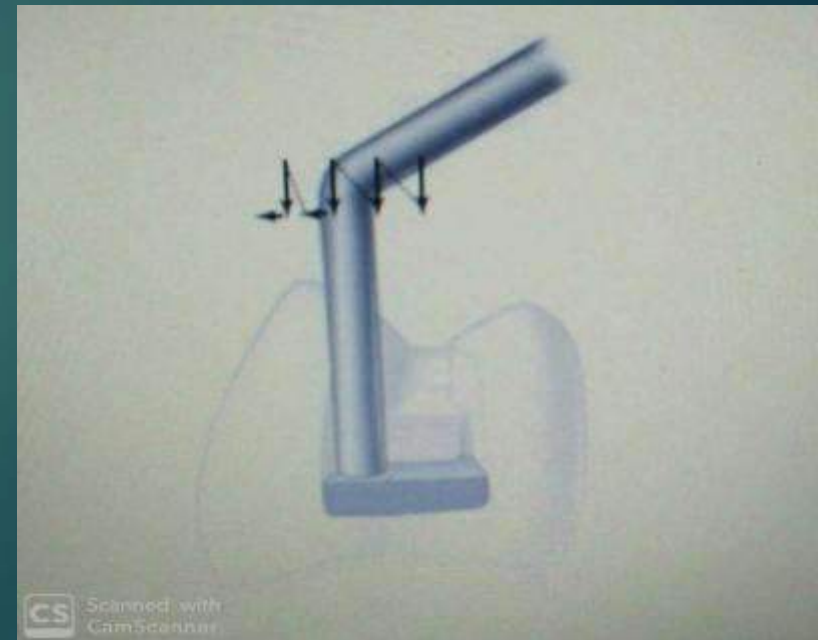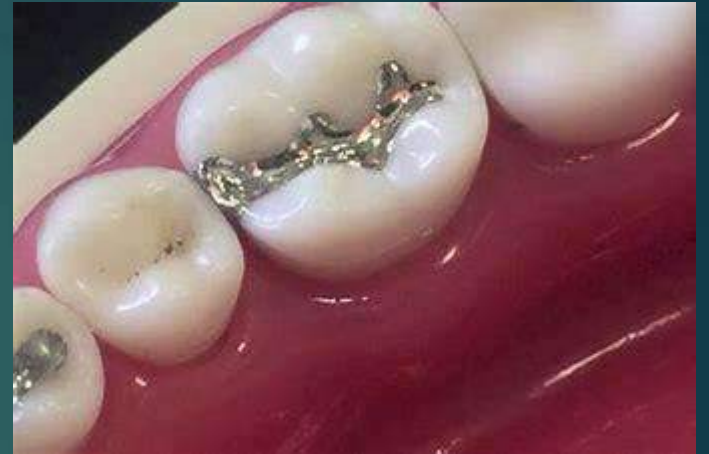- The facial surface on the gingival third is crimped by no. 110 plier to adapt the band to the tooth.
- Proximal contacts and contours are evaluated and adjusted.
- Compound is used to stabilize the band and adjust with the tooth.
- Regardless of the type of matrix system used, the matrix must be stable.



INSERTION AND CARVING OF AMALGAM

The principal objectives during the insertion of amalgam are as follows:

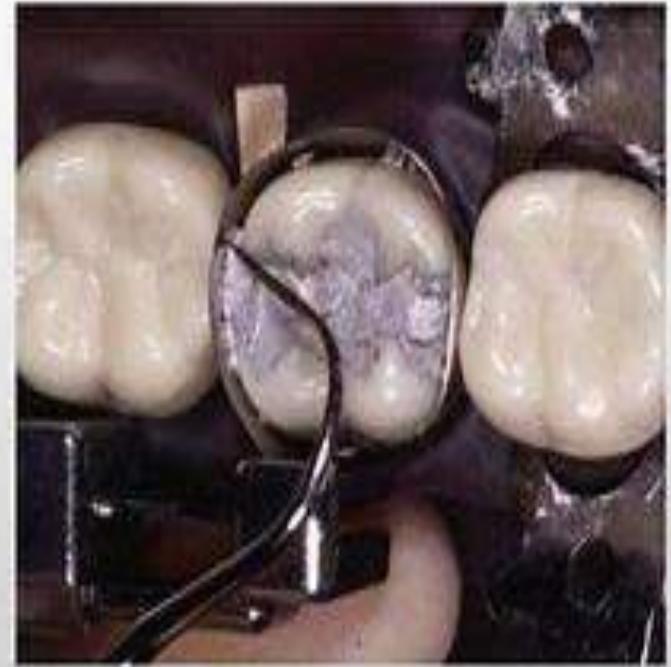- Condensation to adapt the amalgam to the preparation walls and the matrix and to produce a restoration free of voids.
- Keeping the mercury content in the restoration as low as possible to improve strength and decrease corrosion.



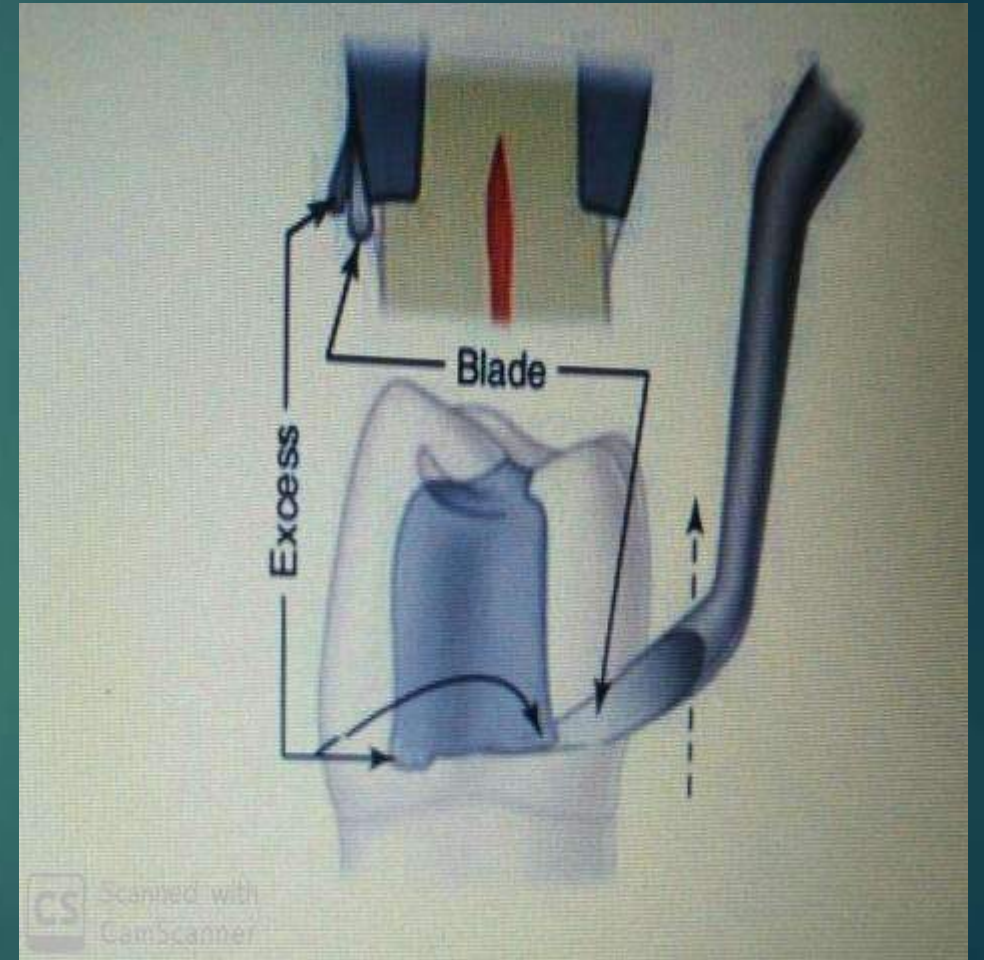
- The procedure of adding and condensing continues until amalgam reaches the level of the pulpal wall.
- The size of the condenser is changed (usually to a larger one), if indicated, and amalgam is condensed in the remaining proximal portion of the preparation concurrently with the occlusal portion.
- The occlusal margins are covered and over-packed by at least 1 mm using a large condenser, ensuring that the margins are well condensed, especially in the area of the marginal ridge (this step ensures prevention of fracture of marginal ridge).

CARVING THE OCCLUSAL PORTION

- Before carving procedures are initiated, precarve burnishing of the occlusal portion with a large egg-shaped or ball burnisher should be done.
- With the matrix band still in place, careful carving of the occlusal portion should begin immediately after condensation and burnishing.
- Sharp discoid instruments of suitable size are the recommended carvers. The larger discoid is used first, followed by the smaller one in regions not accessible to the larger instrument.
- While the matrix is in place, the marginal ridge is carved confluent with the tooth's anatomy such that it duplicates the height and shape of the adjacent marginal ridge.

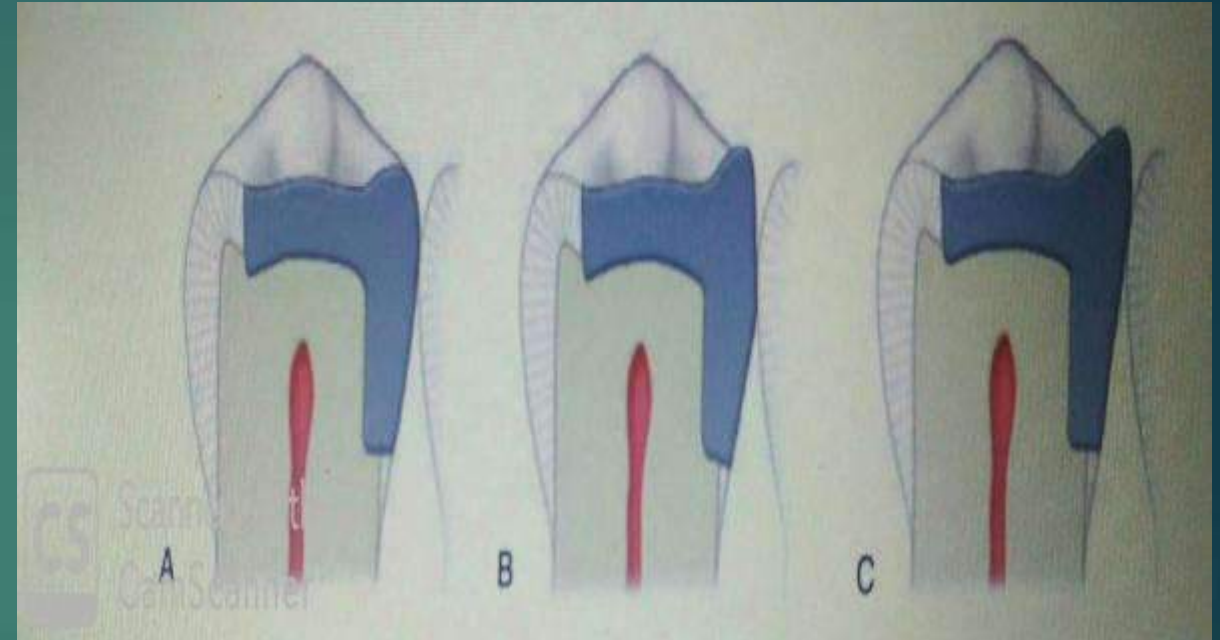


- The objectives would be to develop the general occlusal contour and, most importantly, to develop the correct marginal ridge height and occlusal embrasure form.
- Then, the matrix is removed, and access is gained to carve the axial portions of the restoration. This permits these areas to be carved while amalgam is carvable.
- When the axial carving is completed, the occlusal surface contouring is completed.



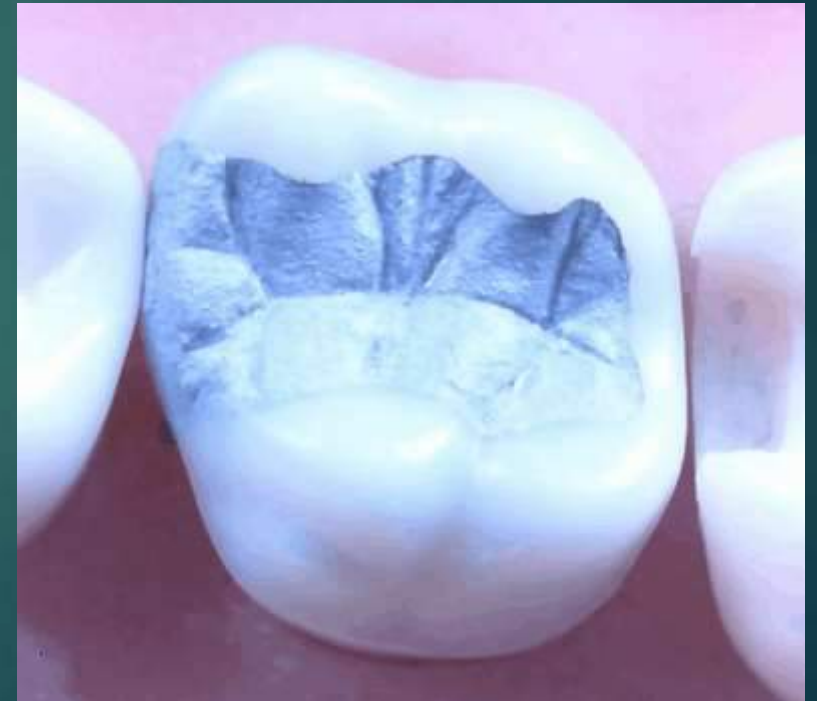REMOVAL OF THE MATRIX BAND AND COMPLETION OF CARVING

- The matrix band (or sectional matrix) and any wedges are gently removed.
- The proximal surface should be nearly completed, with proper contact evident and minimal carving required except to remove a possible small amount of excess amalgam at the proximal facial and lingual margins, at the faciogingival and linguogingival corners, and along the gingival margin.
- The Hollenback carver No. 3 and (occasionally) the side of the explorer may be suitable instruments for carving these areas.
- The existence of the proximal contact is verified visually by using the mouth mirror.
- When carving is completed, the rubber dam is removed, and the occlusion is assessed and adjusted, as needed.



FINISHING AND POLISHING OF AMALGAM

- Finishing of amalgam restorations may be necessary to correct a marginal discrepancy or to improve the contour.
- Polishing an amalgam restoration is not attempted within 24 hours after insertion because crystallization is incomplete.
- Finishing burs or sandpaper disks, rotating at slow speed, may be used to smooth the enamel- amalgam margin.
- When proximal margins are inaccessible to finishing and polishing with disks or rubber polishing points, and some excess amalgam remains (e.g., at the gingival corners and margins), amalgam knives occasionally may be used to trim amalgam back to the margin and to improve the contour.



CONCLUSION

Class I and class II restorations are still common procedures performed by dentists. It is important for practitioners to understand the indications, advantages, techniques and limitations of these restorations.

When used correctly and in properly selected cases, these restorations have the potential to serve for many years.

REFERENCES

- 1.) Harald O Heymann, Edward J Swift, Jr, André V. Ritter, Sturdevant's Art and science of Operative Dentistry, 6th edition, Elsevier, 2012.
- 2.) André V. Ritter Lee W. Boushell, Ricardo Walter, Sturdevant's Art and science of Operative Dentistry, 7th edition, Elsevier, 2018.
- 3) M.A. Marzouk ~ A.L. Simonton R.D. Gross, Operative Dentistry Modern Theory and Practice, All India publishers and distributors Regd. 1997.
- 4) Harald O Heymann, Edward J Swift, Jr, André V Ritter, Sturdevant's Art and Science of Operative Dentistry South asian , Elsevier, 2016.
- 5) Theodore M. Roberson, Harald O Heymann, Edward J Swift, Jr, Sturdevant's Art and science of Operative Dentistry. 5th edition, Elsevier, 2006.
- 6) Peña, Victor & García, R. & García, R.. (2016). Sectional matrix: Step-by-step directions for their clinical use. BDJ. 220. 11-14. 10.1038/sj.bdj.2016.18.

THANK YOU!